SPECIAL ARTICLE – SPECIAL 40 YEARS

Braz J Cardiovasc Surg 2026;41(6):e20260106
https://doi.org/10.21470/1678-9741-2026-0106
ISSN: 1678-9741

The Contemporary Ross Technique: A Stepwise Surgical Guide. Technical Innovations, Patient Selection, and Programme Establishment for Young Surgeons

Francisco Diniz Affonso da Costa[1,2,3], MD, PhD; Andréa Dumsch de Aragón Ferreira[1,2], MD, MsC; Claudinei Collatusso[1,2,3], MD, PhD; Daniele de Fátima Fornazari Collatusso[1,2], MD, PhD; Carolina Limongi de Oliveira[1,2], MD

[1]Departament of Cardiovascular Surgery, Instituto de Neurologia e Cardiologia de Curitiba, Curitiba, Paraná, Brazil.
[2]Departament of Cardiovascular Surgery, Hospital Irmandade Santa Casa de Curitiba, Curitiba, Paraná, Brazil.
[3]Departament of Cardiovascular Surgery, Hospital Infantil Pequeno Príncipe, Curitiba, Paraná, Brazil.

This study was carried out at the Instituto de Neurologia e Cardiologia de Curitiba, Curitiba, Paraná, Brazil.

ABSTRACT

The Ross operation has gained significant renewed interest in recent years. This resurgence is particularly notable among young and middle-aged patients requiring aortic valve replacement. The procedure is increasingly viewed as an optimal alternative, driven by its excellent long-term outcomes, low incidence of valve-related events, and the positive impact on patients' quality of life. This has been reflected in a recent reported European Association for Cardio-Thoracic Surgery consensus on the recommendations of when the Ross operation should be considered as an optimal alternative. However, the operation is technically more complex, and the consensus underscores the importance of careful patient selection and specialized surgical expertise to maximize outcomes. This article provides a detailed, stepwise guide to the contemporary Ross technique, including technical innovations that address late complications, and serves as a resource for young surgeons willing to establish a Ross programme.

Keywords: Ross Operation. Aortic. Valve Replacement. Aortic Valve Disease.

Abbreviations, Acronyms & Symbols	
AVR	= Aortic valve replacement
LV	= Left ventricular
LVOT	= Left ventricular outflow tract
PA	= Pulmonary artery
RVOT	= Right ventricular outflow tract
STJ	= Sinotubular junction

INTRODUCTION

The selection of an optimal valve substitute for aortic valve replacement (AVR) in young adults and middle-aged patients (40 - 60 years) remains a subject of considerable debate and clinical uncertainty[1,2]. While several studies have indicated a modest long-term survival advantage associated with mechanical valves, the requirement for lifelong systemic anticoagulation introduces significant risks and imposes a substantial burden on patients' quality of life[3]. Conversely, recent advancements in anticalcification treatments for biological tissues, coupled with the emergence of transcatheter valve technologies, have led to an increased preference for bioprosthetic valves in patients under 60 years old[4]. This approach is driven by the expectation of enhanced valve durability and the potential for less invasive, percutaneous interventions in the event of structural valve deterioration. Despite these evolving trends, clinical decisions are often made without full consideration of evidence suggesting that AVR with both conventional bioprosthetic and mechanical valves is associated with excess long-term mortality, a phenomenon that appears to be even more pronounced in younger patient populations[5].

The Ross operation has historically faced criticism for its technical complexity, perceived elevated early mortality risk, and potential challenges associated with reoperations[6,7]. Notwithstanding, several recent publications have demonstrated that when performed at experienced centers, the Ross operation carries low

Correspondence Address:
Francisco Diniz Affonso da Costa
Department of Cardiology and Cardiovascular Surgery, Instituto de Neurologia e Cardiologia de Curitiba
Rua Henrique Coelho Neto, 55, Curitiba, PR, Brazil
Zip Code: 82200-120
E-mail: fcosta13@mac.com

Editor-in-chief: Henrique Murad
Associate Editor: Not assigned

How to cite: Costa FDA, Ferreira ADA, Collatusso C, Collatusso DFF, Oliveira CL. The Contemporary Ross Technique: A Stepwise Surgical Guide. Technical Innovations, Patient Selection, and Programme Establishment for Young Surgeons. Braz J Cardiovasc Surg. 2026;41(6):e20260106.doi: 10.21470/1678-9741-2026-0106.

Article received on March 16th, 2026.
Article peer reviewed on Fast Track.
Article accepted on March 17th, 2026.

operative risks and provides patients with near-normal long-term survival, extending for at least two decades post-surgery[8-11]. These findings have contributed to a growing consensus that the procedure is a viable and effective option for appropriately selected individuals. Recent editorials have emphasized the advantages of the "autologous principle", where the patient's own tissue is used, and have argued that the underutilization of the Ross operation represents a missed opportunity to offer optimal outcomes to many young adults with aortic valve disease[12]. This body of evidence has prompted the European Association for Cardio-Thoracic Surgery (or EACTS) to issue an Expert Consensus Statement. The statement generally recommends considering Ross operation for patients aged 60 years or younger, with few comorbidities, and an anticipated life expectancy of at least 15 years[13]. This resurgence in support for the Ross operation was further highlighted by Mazine A et al. at the 2024 American Association for Thoracic Surgery meeting, where a significant increase in the number of Ross operation performed in the United States of America over the past five years was reported[14]. This trend reflects a growing recognition of the operation's benefits and a shift toward broader adoption in clinical practice.

In our practice, the Ross operation has been offered to children and young adults since 1995. With more than 650 procedures performed, our experience has allowed us to refine the technique that may avoid or minimize late complications such as autograft root dilatation with progressive valve insufficiency and right ventricular outflow tract (RVOT) homograft dysfunction[15,16]. This document aims to provide a detailed, step-by-step description of our current approach, along with practical tips and tricks to assist younger surgeons who wish to incorporate the Ross operation into their daily practice. A supplemental video demonstrates an operation performed in a patient presenting with a mixed aortic valve lesion, significant dilatation of the aortic annulus, and an ascending aortic aneurysm. The procedure is a Ross operation, complemented by external annuloplasty and replacement of the ascending aorta using a Dacron® graft. Deep hypothermia was employed to facilitate an open distal anastomosis (Video 1).

Link of the video: https://drive.google.com/file/d/1A6hcmH-j6ZYeFJRMY-iBmhfCKIK0IDVWY/view?usp=drive_link

THORACOTOMY, EXPOSURE, AND EXTRACORPOREAL CIRCULATION SETUP

The procedure begins with a conventional median sternotomy. Once access to the thoracic cavity is achieved, the pericardium is opened longitudinally in an inverted T shape. The pericardial edges are then secured to the anterior border of the sternum on both sides using stay sutures. This maneuver anteriorly displaces the heart and great vessels, enhancing exposure throughout the operation.

Arterial cannulation is performed distally on the aortic arch, immediately after the origin of the brachiocephalic artery. This strategic placement maximizes the working space in the ascending aorta, which is particularly important in cases involving a dilated or aneurysmatic ascending aorta, where an extensive aortoplasty or ascending aortic tube graft replacement with open distal anastomosis with deep hypothermic circulatory arrest may be required. Additionally, aortic arch cannulation improves visualization of the pulmonary artery (PA) bifurcation and facilitates both the harvesting of the autograft and the distal anastomosis of the homograft during RVOT reconstruction.

For venous access, bi-caval cannulation is typically employed to prevent air from entering the venous line during RVOT reconstruction. However, a two-stage venous cannula can also be used as an alternative. A left ventricular (LV) vent is an essential component of the setup. It is preferably inserted through the right superior pulmonary vein, but insertion through the LV apex is also an option if needed. Proper venting is crucial for decompression and maintaining a clear bloodless field during cardiopulmonary bypass.

Routine cases are conducted under moderate hypothermia (32°C), unless deep hypothermia and circulatory arrest are indicated for ascending aorta or hemiarch graft replacement. Myocardial protection is achieved using Del Nido cardioplegia solution. If the aortic valve is competent or has only mild insufficiency, the solution is administered via the aortic root. In the presence of moderate or severe aortic valve regurgitation, direct administration into the coronary ostia is preferred. In certain scenarios such as small aortic roots, prior AVR, or bacterial endocarditis, retrograde cardioplegia may be utilized, especially when initial visualization of the coronary ostia is challenging.

AORTIC VALVE EXPOSURE, RESECTION, AND ROOT ANALYSIS

After establishing cardiopulmonary bypass, the PA is carefully dissected free from the aorta. The dissection extends from the distal bifurcation of the PA down to the proximal pulmonary infundibulum. This step ensures the pulmonary autograft is mobilized adequately for transplantation.

The aorta is cross-clamped, and a transverse incision is then made 0.5 to 1.0 cm above the sinotubular junction (STJ). This precise placement of the incision facilitates access to the aortic root while preserving anatomical landmarks necessary for later reconstruction. To enhance exposure of the proximal aortic root, a retraction suture is placed in the distal aorta. Additionally, three stay sutures are positioned above each commissure or raphe, providing optimal access to the aortic valve for subsequent excision and debridement. A thorough analysis of the aortic valve phenotype is then performed to assess the leaflet structure and commissural arrangement. The valve leaflets are excised, and any annular calcium present is meticulously debrided. Complete removal of calcification is critical to provide a smooth surface for the autograft.

At this stage, measurements of the diameter of the aortic annulus and STJ, the height of the commissures and/or raphes, and the symmetry of the commissures are noted. These measurements are crucial for comparison with that of the pulmonary autograft. Any mismatch between the autograft and the aortic root may need careful adjustments to ensure that the pulmonary autograft will fit anatomically with the aortic root, minimizing the risk of regurgitation or stenosis and promoting long-term durability of the neo-aortic valve.

HARVESTING OF THE PULMONARY HOMOGRAFT AND RIGHT VENTRICULAR OUTFLOW TRACT RECONSTRUCTION

The process of harvesting the pulmonary autograft begins with the assistant utilizing a cardiotomy sucker. This tool is applied with traction at the base of the left ventricle, specifically near the left atrial appendage. The purpose of this maneuver is to straighten the main PA, providing optimal exposure and alignment for the subsequent surgical steps.

Once the main PA is adequately straightened, the first surgical incision is performed. A circumferential incision is made distally, just a few millimeters below the bifurcation of the PA. After the artery has been incised, the pulmonary valve is meticulously inspected, and the surgeon carefully examines the valve structure for any malformations or significant fenestrations. Such abnormalities, although rare, can render the autograft unsuitable for transplantation. According to personal experience, major malformations or fenestrations are uncommon but may be encountered in approximately 1% of cases.

The proximal dissection of the pulmonary autograft begins posteriorly with low-power electrocautery to separate the loose connective tissue between the PA and the left main coronary artery. Electrocautery is also used to carefully dissect the fat on the lateral side of the PA, with particular attention to preserving the left anterior descending artery that courses nearby. Before starting the anterior incision on the pulmonary infundibulum, a Mixter clamp is introduced from inside the PA toward the nadir of the anterior pulmonary valve cusp, ensuring its accurate localization since its location by the external appearance on the infundibulum may be misleading and result in damage to the valve. The first 3 cm of the infundibular incision is made with a scalpel and continued medially with scissors, leaving no more than 3 – 5 mm of muscle beneath the valve cusps, which are now directly visualized. With the autograft retracted anteriorly, a clear plane of dissection becomes evident, and the posterior muscle of the infundibulum is dissected from the interventricular septum, maintaining a 3-mm margin below the cusps. Special care is required to avoid injury to the first septal branch, that runs in a muscular band below the nadir of the left-facing cusp. One should remember that this artery has variable size and sometimes is quite large and superficial, and a damage could precipitate malignant ventricular arrhythmias postoperatively.

After harvesting the pulmonary autograft, it is essential to ensure thorough hemostasis in the donor area, as this region can become difficult to access later in the operation. While administering cardioplegia through the left coronary ostia, small arterial and venous bleeders are typically managed with electrocautery whereas occasional diffuse venous bleeding may require meticulous local suturing. Following harvest, the autograft is trimmed in a scalloped manner, preserving a 2 – 3 mm rim of muscle. However, in patients presenting with unicuspid or certain bicuspid aortic valve phenotypes, the muscle is trimmed in a linear fashion to facilitate later symmetrical implantation within abnormal aortic roots. After preparation, the autograft is immersed in warm blood to preserve tissue viability until implantation in the systemic circulation.

In RVOT reconstruction, a cryopreserved or decellularized homograft is employed, with preference for an oversized conduit (≥ 26 mm) to mitigate the risk of late pulmonary stenosis due to shrinkage. The left ventricle is retracted caudally using a narrow malleable lung retractor to enhance exposure of the PA bifurcation during distal homograft anastomosis, which is performed with continuous 4-0 or 5-0 polypropylene suture. Prior to final suture tying, a Hegar dilator of at least 24 mm is inserted through the anastomotic site to prevent stenosis from the purse-string effect. The proximal anastomosis is similarly executed with a running 4-0 polypropylene suture, with meticulous attention to avoid injury to the left anterior descending artery, located laterally, and careful suture placement in the region of the first septal perforator branch. This technique optimizes conduit patency and minimizes vascular complications.

We developed a technical modification in pulmonary homograft preparation involving the creation of a conical extension at the proximal end of the homograft using a patch of decellularized human pericardium. This modification allows for a wider proximal anastomosis, enhancing blood flow and minimizing the risk of postoperative narrowing, while also preventing late fibrosis and shrinkage that commonly result in distortion, stenosis, and valve insufficiency. Clinical follow-up has demonstrated improved hemodynamic outcomes and reduced pressure gradients across the homograft at late intervals, confirming the sustained benefit of this approach. Intraoperatively, before final implantation, the right ventricle is filled with blood from extracorporeal circulation and thoroughly deaired, optimizing graft seating and reducing the risk of air embolism. In our opinion, the conical extension technique with decellularized pericardium represents a significant improvement in RVOT reconstruction, associated with sustained low late gradients and valve competence.

PULMONARY AUTOGRAFT IMPLANTATION

After completion of the right-sided portion of the surgical procedure, focus shifts back to the aortic root for autograft implantation, which is most commonly performed as a total root replacement. Before detachment of the coronary buttons, an additional half dose of Del Nido cardioplegia is administered to optimize myocardial protection. This single supplemental dose is generally sufficient to maintain myocardial arrest and protection for the remainder of the operation.

We then create the left and right coronary buttons, and using electrocautery, we make a dissection parallel to the remnants of the aortic wall, extending towards the left atrial dome and the interventricular septum. This meticulous dissection aims to fully mobilize the coronary buttons, facilitating their future reimplantation and minimizing the risk of kinking, which is essential for optimal postoperative coronary flow. Concurrently, the native non-coronary sinus wall and the remnant of the left-right commissural post are intentionally preserved; these structures are maintained to provide robust external support for the autograft during the final stages of the operation, which is important to avoid late dilatation of the pulmonary autograft and improved late outcomes.

Implantation of the autograft in the left ventricular outflow tract (LVOT) as a root replacement necessitates meticulous attention to the marking and adaptation of reference points to ensure optimal anatomical and functional outcomes. Before proceeding with the implantation, three equidistant points, each 120 degrees apart, should be clearly marked on both the autograft and the aortic annulus. In tricuspid valves, these reference points are ideally positioned at or near the native commissures to preserve anatomical orientation and facilitate straightforward reimplantation of the coronary arteries. However, in cases involving bicuspid valve phenotypes — and particularly in unicuspid valves — the placement of these reference points in the aortic annulus must be carefully modified. The primary aim in these situations is to enable coronary reimplantation to be executed without tension, ensuring that the coronary ostia are situated away from the commissures of the autograft. This may require positioning the reference points away from the native commissures to minimize anatomical stress and promote optimal coronary flow.

Implantation of the autograft in the aortic annulus is optimally achieved using single interrupted polyester 4-0 sutures, a technique that ensures precise geometric orientation without distortion, thereby minimizing the risk of cusp prolapse and subsequent aortic insufficiency. The individually placed interrupted sutures allow for meticulous adjustment, maintaining the autograft's natural alignment within the annulus and preserving the physiological motion of the aortic root throughout all phases of the cardiac cycle. Implantation of an aortic autograft necessitates precise intra-annular placement, as the absence of fibrous external annular support mandates that the native aortic annulus provides long-term stability and reduces the risk of late dilatation. Proper orientation is critical: the left-facing (bare) sinus of the autograft must be positioned into the left coronary sinus of the aortic root, ensuring support from posterior mediastinal structures. Sutures are introduced 1 – 2 mm above the aortic annulus and exit 2 – 3 mm within the LVOT; subsequently, the same suture is passed from inside the autograft, beginning 1 mm below the leaflet rim in an oblique direction and exiting 2 – 3 mm above the hinge point. Sutures are sequentially placed in the right coronary sinus, left coronary sinus, and then the non-coronary sinus. Throughout this process, it is essential to align the three equidistant 120° points of the autograft with corresponding points in the aortic annulus to ensure optimal anatomical integration, secure anchoring, and long-term functional success of the autograft valve.

The proximal suture line can be reinforced to enhance hemostasis and provide additional external support using two primary techniques. The preferred approach is to employ a continuous 4-0 polypropylene suture, approximating the remnants of the native aortic walls with the adventitia of the autograft, which ensures a secure and hemostatic closure by closely aligning the tissue layers and minimizing bleeding. Alternatively, while tying the proximal suture line of the autograft, a Teflon™ felt strip can be incorporated to add extra strength and external support; the felt serves as a buttress, distributing tension and reducing the risk of suture line disruption, particularly in fragile or compromised tissues. Both methods are valuable for reinforcing the proximal suture line, with the choice determined by the surgeon's preference and the patient's specific clinical scenario.

The anastomosis of coronary buttons to the corresponding sinuses of the autograft is performed using 6-0 polypropylene sutures. The compliant nature of the autograft reduces the likelihood of excessive tension or kinking, in contrast to more rigid prosthetic roots. In patients with symmetric aortic roots, the coronary anastomoses are typically centered within each sinus just below the STJ. However, in anatomical variations such as unicuspid or bicuspid aortic valves, it may result in displacement of the native coronary ostia, requiring the surgeon to assess individual anatomy and adjust the anastomosis location accordingly in order to avoid tension or distortion.

The distal anastomosis is a vital stage in autograft aortic surgery, requiring careful preparation to minimize the risk of late STJ dilatation and secondary aortic regurgitation. The autograft is trimmed, leaving only 2 - 3 mm of supra-commissural PA wall. When the distal aorta's diameter is normal and there is no mismatch (≤ 2 - 3 mm), a standard anastomosis with continuous 5-0 polypropylene sutures is performed, and three matching, equidistant points are marked on both the autograft and ascending aorta to avoid distortion of intercommissural distances, which could otherwise lead to cusp prolapse. If the ascending aorta exhibits dilatation, an aortoplasty is carried out by resecting a triangular segment of aorta to match its diameter to the autograft, thus reducing suture line tension and preventing leakage or further dilatation. In cases of moderate dilatation (about 4.0 cm), particularly when the aortic tissue is fragile or aneurysms are present, the ascending aorta is replaced with a Dacron® tube graft of suitable size. The cross-clamp is removed, protamine is administered to allow normal clotting, and meticulous hemostasis is performed to stop bleeding. The final essential step involves tacking the native non-coronary sinus wall and the native left-right commissural wall to the ascending aorta just above the distal anastomosis. This technique provides additional external support to the autograft, reinforcing its structural integrity and minimizing the risk of late dilatation and valve insufficiency.

THE INCLUSION TECHNIQUE

The inclusion technique is an alternative approach to the traditional full root replacement technique. While both techniques share many operative steps, the inclusion technique avoids mobilizing the coronary buttons; instead, the native root is left intact, and the pulmonary autograft is implanted inside the preserved root. This approach offers the advantage of enhanced structural support for the autograft, which may help reduce the risk of dilation.

Following autograft harvesting and RVOT reconstruction, the native aortic root is incised down to the base of the non-coronary sinus to enhance surgical exposure. The proximal suture line for autograft insertion is established using interrupted 4-0 polyester sutures, identical to the technique used for total root replacement, though no reinforcement is employed at this level. For coronary reimplantation, holes are fashioned in the centers of the left and right coronary sinuses of the autograft, and coronary anastomoses are performed side-to-side utilizing 6-0 polypropylene sutures. Upon completion, the distal end of the autograft is trimmed, followed by direct anastomosis with the distal ascending aorta, restoring continuity of the aortic pathway. Finally, the non-coronary sinus of the native root is closed, and the native root is tacked just above the autograft-aorta anastomosis, fully enclosing the autograft within the native root structure.

A major disadvantage with this technique is the difficulty, and sometimes impossibility, of achieving surgical hemostasis at potential bleeding sites after the aorta has been unclamped, as access is often severely limited. The technique is best suited for individuals with normal or only mildly dilated native aortic roots, where the anatomical conditions are favorable and the risks minimized; however, it is not suitable or recommended for those with small aortic roots or with pronounced dilatation of the aortic annulus and sinuses of Valsalva. Ultimately, careful evaluation of the patient's aortic root anatomy is essential to determine the appropriateness and anticipated benefits of this approach.

PATIENTS WITH AORTIC VALVE INSUFFICIENCY AND DILATED ROOTS

The root replacement technique for treating patients with aortic insufficiency and a dilated aortic root is fundamentally similar to the procedure used for aortic stenosis with normal root dimensions, but it requires several key modifications to address anatomical and technical challenges.

Reducing the diameter of the aortic annulus is necessary in patients whose native annulus is larger than the autograft, to ensure an optimal fit and proper function. This is accomplished using an

extra-aortic annuloplasty band, as adapted from valve-sparing root replacement techniques. The procedure involves placing six or twelve 2-0 pledgeted sutures horizontally, passing from the inside of the LVOT at the basal ring level to the outside of the aorta. These sutures are then symmetrically anchored through a circular Teflon™ band, which is selected to be about 6 mm larger in diameter than the autograft to accommodate the aortic root's thickness. Once all sutures are tied, the annular diameter is reduced to match the autograft. A key difference from the standard root replacement sequence is that the aortic annuloplasty is performed before the pulmonary homograft is implanted to reconstruct the RVOT. This order is critical because the annuloplasty sutures at the right-left commissure exit in the upper interventricular septum, a position that would later be obscured by the proximal suture line of the right-sided homograft, making suture placement and management more challenging.

This sub-group of patients invariably have some degree of ascending aorta dilatation. The treatment strategy is determined by both the severity of the dilatation and the integrity of the aortic tissue. When the dilatation is mild or moderate and the aortic wall possesses adequate thickness and strength, a triangular aortoplasty is typically sufficient, reshaping and preserving the native vessel. However, in situations where the dilatation is more severe — defined as a diameter of 4.2 to 4.5 cm or greater — or when the tissue is aneurysmatic, thin, or fragile, surgical replacement of the ascending aorta and hemiarch with a Dacron® tube graft is necessary.

Covering the autograft with the aortic native non-coronary sinus and the aortic left-right commissural remnants is particularly recommended in these patients to minimize the risk of future autograft dilatation.

THE ROSS-KONNO OPERATION

In pediatric cardiology, some children and adolescents present with congenital bicuspid or unicuspid aortic valves and small, hypoplastic aortic roots, creating challenges during procedures like the Ross operation, especially when a larger autograft must be accommodated. The need for aortic root enlargement depends on the degree of size mismatch between the autograft and the native root; when this mismatch is mild, less invasive techniques such as the Manougian and Nicks methods — both involving the insertion of a small patch of pericardium to modestly expand the annulus — are usually sufficient. However, in cases of true hypoplasia where the root is considerably undersized, more extensive intervention is required: the Ross-Konno operation combines the Ross procedure with a Konno enlargement, allowing for significant widening of the aortic root via septal incision.

The operation closely resembles the conventional technique but incorporates several important adjustments, particularly during the harvesting of the pulmonary autograft. At the time of harvesting the pulmonary autograft, the anterior incision is made on the pulmonary infundibulum, positioned 1 cm more proximally than in the standard approach. This alteration purposefully leaves a wider and longer rim of muscle tissue beneath the valve cusps. The preserved muscle rim is subsequently utilized to cover the defect created by the incision into the interventricular septum.

After completion of autograft harvest, careful preparation of the aortic root is essential and includes excision of the native aortic valve leaflets, creation of the coronary buttons by mobilizing the coronary arteries for later reimplantation, and removal of all aortic sinus remnants to provide an unobstructed field for subsequent graft placement. Following this, a longitudinal incision approximately 1 cm in length is made in the interventricular septum, beginning at the right coronary sinus near the right-left commissure and extending 1 to 1.5 cm downward into the septal tissue. Precise location of this incision is critical to avoid interference with the proximal homograft anastomosis during RVOT reconstruction. In cases where the interventricular septum is notably hypertrophied, judicious muscle shaving at the incision site may be performed to increase the diameter of the LVOT.

The proximal anastomosis of the autograft is performed at the level of the left and non-coronary sinuses using interrupted single 4-0 polyester sutures placed in a conventional manner. At the site of the right coronary or interventricular septum incision, pledgeted U sutures are placed, first anchoring into the enlarged LVOT to provide robust support in areas subject to increased tension, and then through any extra muscle intentionally left on the autograft, thereby reinforcing the mechanical strength of the repair.

Hypoplasia of the ascending aorta is frequently observed in these patients, causing significant mismatch between the native aorta and the autograft diameter. This is addressed by enlarging the ascending aorta with a patch of pericardium to a diameter similar of that of the autograft. This enlargement technique is crucial for matching diameters, preventing stenosis or turbulence at the anastomosis site.

CONCLUSION

The Ross operation is a highly demanding technique for AVR. Its complexity requires rigorous training and experience to ensure both low operative mortality and favorable long-term outcomes. Surgical consensus affirms that this procedure should be performed in specialized reference centers, ideally with high volumes of cases and by surgeons experienced in aortic root surgeries. Since 1995, our institution has performed more than 650 Ross operations across a diverse patient population, spanning various ages and etiologies of aortic valve disease, including those with endocarditis and/or multiple reoperations. The long-term survival rate for the overall cohort stands at 77.9% at 28 years, as illustrated in Figure 1. Notably, after 20 years of follow-up, the need for reoperation on the pulmonary autograft was 14%, and the rate for RVOT homograft was 9%. Valve-related adverse events have remained low, and most patients are classified as New York Heart Association (or NYHA) class I or II, indicating mild or no symptoms. Over the years, the Ross operation has undergone several techni-

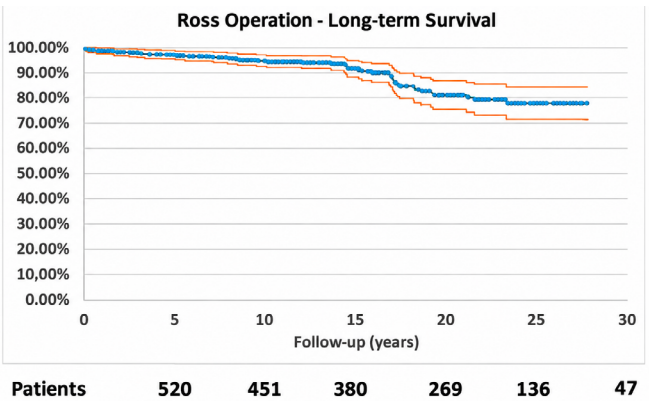

Fig. 1 - *Long-term survival after Ross Operation.*

cal refinements to address late complications such as aortic root dilatation and progressive valve insufficiency, which are expected to further improve outcomes. Additionally, new tissue engineering technologies applied during homograft preparation have reduced the incidence of RVOT homograft dysfunction and decreased the need for subsequent reinterventions. Given the superior survival rates and quality of life improvements seen especially in children and young adults with aortic valve disease, institutions are encouraged to establish dedicated Ross programs. Such initiatives should involve proper training, high procedural volumes, and ongoing technical innovation to offer optimal patient outcomes. In summary, when performed in expert centers and supported by continued advancements, the Ross operation provides excellent long-term survival and quality of life for patients with aortic valve disease, underscoring the significance of specialized training and institutional commitment.

Data Availability

The authors declare that the data supporting the findings of this study are available within the article.

Artificial Intelligence Usage

The authors declare use of Chat GPT - CoPilot for grammar corrections. The content produced by the artificial intelligence tool was revised and edited by the authors as necessary, and they take full responsibility for the content to be published.

Sources of Funding

The authors declare no external funding to this study.

Potential Conflict of Interest

The authors declare that there is no conflict of interest in this study.

Authors' Roles & Responsibilities

FDAC	Substantial contributions to the conception or design of the work; drafting the work or revising it critically for important intellectual content; final approval of the version to be published
ADAF	Agreement to be accountable for all aspects of the work; final approval of the version to be published
CC	Agreement to be accountable for all aspects of the work; final approval of the version to be published
DFFC	Agreement to be accountable for all aspects of the work; final approval of the version to be published
CLO	Agreement to be accountable for all aspects of the work; final approval of the version to be published

REFERENCES

1. Weber A, Noureddine H, Englberger L, Dick F, Gahl B, Aymard T, et al. Ten-year comparison of pericardial tissue valves *versus* mechanical prostheses for aortic valve replacement in patients younger than 60 years of age. J Thorac Cardiovasc Surg. 2012;144(5):1075-1083. doi:10.1016/j.jtcvs.2012.01.024.
2. Bowdish ME, Mehaffey JH, Chang SC, O'Gara PT, Mack MJ, Goldstone AB, et al. Bioprosthetic *vs.* mechanical aortic valve replacement in patients 40 to 75 years of age. J Am Coll Cardiol. 2025;85(12):1289-1298. doi:10.1016/j.jacc.2025.01.013.
3. Goldstone AB, Chiu P, Baiocchi M, Lingala B, Patrick WL, Fischbein MP, et al. Mechanical or biologic prostheses for aortic-valve and mitral-valve replacement. N Engl J Med. 2017;377(19):1847-1857. doi:10.1056/NEJMoa1613792.
4. Salna M, Bavaria JE, Heimansohn D, Beaver T, Griffith B, Svensson LG, et al. Seven-year results for RESILIA tissue in bicuspid aortic valve replacement patients: age and valve size considerations. Interdiscip Cardiovasc Thorac Surg. 2025;40(8):ivaf176. doi:10.1093/icvts/ivaf176.
5. Mazine A, Ouzounian M. Aortic valve replacement in young and middle-aged adults: looking beyond the tree that hides the forest. Ann Transl Med. 2017;5(4):92. doi:10.21037/atm.2017.02.06.
6. El Sherif N, Dearani JA, Connolly HM, Bagameri G, Pochettino A, Stulak JM, et al. Complexity and outcome of reoperations after the Ross procedure in the current era. Ann Thorac Surg. 2023;115(3):633-639. doi:10.1016/j.athoracsur.2022.05.017.
7. Williams EE, El-Hamamsy I. The Ross procedure: total root technique. Ann Cardiothorac Surg. 2021;10(4): 546-548. doi:10.21037/acs-2020-rp-229.
8. Caldaroni F, Skillington P, O'Keefe M, Buratto E, Wynne R. Twenty-five years of the Ross operation in adults: the inclusion technique keeps up the expectations. J Thorac Cardiovasc Surg. 2025;170(4):1017-1024.e1. doi:10.1016/j.jtcvs.2025.01.007.
9. Mazine A, El-Hamamsy I, Verma S, Peterson MD, Bonow RO, Yacoub MH, et al. Ross procedure in adults for cardiologists and cardiac surgeons: JACC state-of-the-art review. J Am Coll Cardiol. 2018;72(22):2761-2777. doi:10.1016/j.jacc.2018.08.2200.
10. David TE, David C, Woo A, Manlhiot C. The Ross procedure: outcomes at 20 years. J Thorac Cardiovasc Surg. 2014;147(1):85-93. doi:10.1016/j.jtcvs.2013.08.007.
11. Réa ABBAC, Affonso da Costa FD, Adam EL, El-Hamamsy I, Balbi Filho EM, Oliveira CL, et al. Long-term results of the Ross operation in rheumatic valve disease. Eur J Cardiothorac Surg. 2022; ezac487. doi:10.1093/ejcts/ezac487.
12. Yacoub MH, El-Hamamsy I, Sievers HH, Carabello BA, Bonow RO, Stelzer P, et al. Under-use of the Ross operation--a lost opportunity. Lancet. 2014;384(9943):559-560. doi:10.1016/S0140-6736(14)61090-4.
13. Vojacek J, Gofus J, Andreas M, Bavaria JE, Berdajs D, Casselman FPA, et al.; EACTS Scientific Document Group. EACTS expert consensus statement on the Ross procedure in adult patients. Eur J Cardiothorac Surg. 2026;68(2):ezaf295. doi:10.1093/ejcts/ezaf295.
14. Mazine A, Weiss J, Chikwe J, Desai ND, Chung JC, Malas J, et al. Use of the Ross procedure in North America: relation between surgical volume and operative mortality. J Am Coll Cardiol. 2026;87(24):3384-3396. doi:10.1016/j.jacc.2026.01.031.
15. da Costa FD, Takkenberg JJ, Fornazari D, Balbi Filho EM, Colatusso C, Mokhles MM, et al. Long-term results of the Ross operation: an 18-year single institutional experience. Eur J Cardiothorac Surg. 2014;46(3):415-422; discussion 422. doi:10.1093/ejcts/ezu013.
16. Réa ABBADC, da Costa FDA, Adam EL, Colatusso C, Oliveira CL, Fernandes da Silva MM. Improving outcomes of right ventricular outflow tract reconstruction during the Ross operation: homograft decellularization and surgical technique. JTCVS Open. 2025;25:25-38. doi:10.1016/j.xjon.2025.01.020.

This is an open-access article distributed under the terms of the Creative Commons Attribution License.