ORIGINAL ARTICLE – SPECIAL 40 YEARS

Braz J Cardiovasc Surg 2026;41(6):e20260180
https://doi.org/10.21470/1678-9741-2026-0180
ISSN: 1678-9741

State of The Art of The da Silva's Cone Operation for Treatment of Ebstein's Anomaly

José Pedro da Silva[1,2], MD; Victor Morell[1], MD; Marcelo Matos Cascudo[3], MD; Mario Castro-Medina[1], MD; Rodrigo Freire Bezerra[2], MD; Rodrigo Moreira Castro[2], MD; José Cícero Guilhen[4,5], MD; Luciana Da Fonseca Da Silva[1], MD

[1]Department of Cardiothoracic Surgery, UPMC Children's Hospital of Pittsburgh, Da Silva Center for Ebstein Anomaly, Heart Institute, University of Pittsburgh Medical Center, Pittsburgh, Pennsylvania, United States of America.
[2]Department of Cardiovascular Surgery, Hospital Beneficência Portuguesa de São Paulo, São Paulo, São Paulo, Brazil.
[3]Department of Cardiovascular Surgery, Hospital Rio Grande and Instituto do Coração (Incor), Natal, Rio Grande do Norte Brazil.
[4]Department of Cardiovascular Surgery, Escola Paulista de Medicina, Universidade Federal de São Paulo.
[5]Hospital Dante Pazzanezi, São Paulo, São Paulo, Brazil.

This study was carried out at the Department of Cardiothoracic Surgery, UPMC Children's Hospital of Pittsburgh, Da Silva Center for Ebstein Anomaly, Heart Institute, University of Pittsburgh Medical Center, Pittsburgh, Pennsylvania, United States of America.

ABSTRACT

Ebstein's anomaly (EA) is a complex congenital heart disease caused by embryological failure of the tricuspid valve (TV) leaflet delamination, leading to displacement of the leaflets and right ventricular myopathy. In 1958, Hunter and Lillehei began developing surgical techniques for the repair of EA. Their technique was followed by many others. However, those techniques presented significant limitations due to the wide range of anatomical variations in the disease. The Da Silva Cone repair (CR) for EA emerged as the most anatomical repair technique for all forms of the disease, yielding the best results for most patients. Since CR can be performed with low mortality and morbidity, is effective and durable, and rarely requires TV replacement, it has been widely adopted. It allowed that surgical intervention can be indicated before the development of significant right ventricular dilatation or dysfunction. CR can be applied to any age, but it carries more risk in the neonate with critical EA. Therefore, neonates with critical EA may benefit from a staged approach, performing the Starnes procedure in the neonatal period and the CR later. The 2025 American Association for Thoracic Surgery expert consensus on managing EA covered preoperative evaluation, surgical indications, and contraindications in neonates, children, and adults. Additionally, the expert consensus discussed the approach to cardiac arrhythmias associated with EA and alternative procedures for select cases, including TV replacement and a bidirectional cavopulmonary shunt, depending on patient characteristics. They also agreed that the CR repair of the TV is beneficial when surgery is indicated.

Keywords: Ebstein's Anomaly (EA). Congenital Heart Disease. Tricuspid Valve. Cardiac Surgery. Echocardiography.

Abbreviations, Acronyms & Symbols

AATS	= American Association for Thoracic Surgery	P	= Plication
AL	= Anterior leaflet	PDA	= Patent ductus arteriosus
ARV	= Atrialized right ventricle	PFO	= Persistent foramen ovale
ASD	= Atrial septal defect	PO	= Postoperative
C	= Cone	Preop	= Preoperative
Cc	= Cone closed	PTFE	= Polytetrafluoroethylene
CR	= Cone repair	PV	= Pulmonary valve

Correspondence Address:
José Pedro da Silva
Department of Cardiothoracic Surgery, UPMC Children's Hospital of Pittsburgh, Da Silva Center for Ebstein Anomaly, Heart Institute, University of Pittsburgh Medical Center
4401 Penn Av, Pittsburgh, PA, United States of America
Zip Code: 14214
E-mail: dasilvajp@upmc.edu

Editor-in-chief: Henrique Murad
Associate Editor: Not assigned

How to cite: Silva JP, Morell V, Cascudo MM, Castro-Medina M, Bezerra RF, Castro RM, Guilhen JC, Silva LF. State of the art of the da Silva's Cone operation for treatment of Ebstein's anomaly. Braz J Cardiovasc Surg. 2026;41(6):e20260180.doi:10.21470/1678-9741-2026-0180.

Article received on April 26th, 2026.
Article peer reviewed on October 18th, 2026.
Article accepted on October 20th, 2026.

CTI	= Cardiothoracic index	RA	= Right atrium
EA	= Ebstein's anomaly	RV	= Right ventricle
ECMO	= Extracorporeal membrane oxygenation	RVEF	= Right ventricular ejection fraction
F	= Fenestration	SL	= Septal leaflet
FRV	= Functional right ventricle	SS	= Single stitch
IL	= Inferior leaflet	TA	= True annulus
LV	= Left ventricle	TV	= Tricuspid valve
LVEF	= Left ventricular ejection fraction	TVR	= Tricuspid valve replacement
MRI	= Magnetic resonance imaging	TR	= Tricuspid regurgitation
NYHA	= New York Heart Association		

INTRODUCTION

Ebstein's anomaly (EA) is an uncommon congenital heart defect involving the tricuspid valve (TV) and right ventricle (RV), which was first described by the pathologist Wilhelm Ebstein in 1866[1]. Its main features are downward displacement of the septal and posterior leaflets of the TV, dilation of the right atrioventricular annulus, TV regurgitation, and right atrium and right ventricular dilation. Displacement of the septal and posterior leaflets divides the RV into two chambers: the atrialized RV, positioned between the normal atrioventricular junction and the displaced TV, and the functional RV, located distally to the TV. The degree of TV annulus rotation within the RV results in variable functional RV capacitance and a wide range of anatomical forms of EA[2].

THE EVOLUTION OF SURGICAL REPAIR TECHNIQUES

The endeavor to repair EA began in 1958, when Hunter and Lillehei developed a repair technique as a new form of surgical therapy for EA[3]. Unfortunately, they failed to apply their operation because the first patient, a ten-year-old boy, sadly died during the anesthesia induction. Subsequently, Hardy et al. performed the first successful TV repair in EA using the Hunter-Lillehei technique in 1964[4,5].

In 1965, at the University of Pittsburgh, Dr. Bahnson used the Hunter technique in three patients[6]. In Figure 1, you can see that he brought the displaced tricuspid annulus into alignment with the annulus at the normal atrioventricular junction as suggested by Hunter and Lillehei. Therefore, he performed the transverse plication of the atrialized RV.

In 1972, Danielson et al. modified the Hunter technique by performing the right atrial reduction plasty and annuloplasty, improving TV competency[7]. The Danielson's procedure consists of transverse plication of the atrialized right ventricular portion, by placing mattress sutures, passed on the anomalous attachment line of the anterior and posterior tricuspid leaflets, which are subsequently passed through the true TV annulus. Upon tying these sutures sequentially, the displaced leaflets and the true tricuspid annulus are approximated, obliterating the atrialized RV (transverse plication). Next, the inferior part of the tricuspid annulus is plicated to further reduce the tricuspid annulus circumference. This technique, based on the right atrioventricular valve functioning as a monocusp closing against the septum, became one of

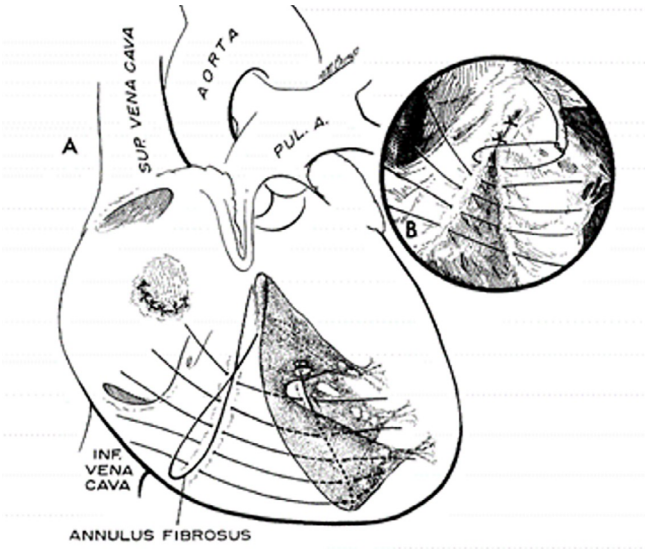

Fig. 1 - *Bahnson application of the Hunter-Lillehei technique in 1965. He performed the transverse plication of the right ventricle atrialized chamber by approximating the displaced tricuspid annulus to the annulus placed at normal atrioventricular junction. (Picture from BAHNSON, BAUERSFELD, SMITH. Circulation 1965; 31:3. Apr 1965). The Creative Commons license does not apply to this content. Use of the material in any format is prohibited without written permission from the publisher, Wolters Kluwer Health, Inc.*

the most widely used surgical repair techniques for the treatment of EA. Many patients have benefited from Danielson's operation for EA. However, the need for a large, mobile anterior leaflet to achieve the goal of correcting tricuspid regurgitation has limited the procedure to a restricted group of anatomical variations. Consequently, it required TV replacement in 36 - 63% of cases[8-10]. The Danielson technique seems to be less efficacious in children; as reported in the Mayo Clinic series of 184 patients under 12 years old, only 28.3% could be repaired with the Danielson technique[10]. This low repair rate is probably because children who need early operation usually present a more complex form of EA.

In 1988, Carpentier et al.[11] described a new technique that increased TV mobility by taking down the anterior and inferior leaflets. He plicated the RV vertically and re-attached it to the normal atrioventricular junction. The Carpentier technique also produces a monocusp valve mechanism. However, by plicating

the atrialized RV and bringing the TV to its anatomically correct level, it yields a better right ventricular morphology compared with Danielson's technique. The Carpentier group remodels and reinforces the TV annulus with a prosthetic ring. They were able to apply this procedure to most anatomical presentations of the disease. Nonetheless, the hospital mortality was high (14%) in their initial series, and long-term complications were also frequent[11,12]. Quaegebeur et al.[13] performed a slight modification of this operation and didn't use a prosthetic ring. They reported that there was no hospital death, but their follow-up data showed a high incidence of moderate and severe degrees of tricuspid regurgitation[14].

Many other surgical techniques were developed. However, the wide variety of anatomical and pathophysiological presentations of EA has made it difficult to achieve uniform results with surgical repair. Among these techniques, we highlight the Hetzer and Sebening procedures. Their techniques were used to treat large numbers of patients in the past and are still used in some centers for certain EA anatomical situations.

The Da Silva Cone Technique

In 1989, we created a new surgical technique designed to address all morphological types of EA, which we began applying to patients in 1993[15]. The surgical concepts of this operation are to undo most of the TV anatomical defects that occurred during its embryological development and create a cone-like structure from all available leaflet tissue. Then, the cone is reattached to the normal atrioventricular junction with the idea of covering 360° of the TV annulus with leaflet tissue, allowing leaflet-to-leaflet coaptation[16]. The Cone repair (CR) mimics the normal TV anatomy and contrasts with the previous procedures that result in a monocusp valve coaptating with the ventricular septum[17]. The international presentation of the Da Silva CR technique in 2006 attracted enormous interest[16], and it was recognized as the first true anatomical repair of EA[17,18]. The CR was widely adopted worldwide and became the gold standard technique for EA repair[17,19-23].

We created the CR after having moderate-to-severe TV regurgitation on our second EA patient, to whom we applied Danielson's repair technique. Fortunately, we were not aware of the recently described Carpentier technique for EA. Otherwise, we would likely use it in the next patient, since our goal was to avoid TV replacement, which is considered an advantage of the Carpentier's repair over Danielson's repair. Although some of our CR maneuvers coincide with the concepts introduced by Carpentier et al.[11], such as TV leaflet mobilization, attachment of the leaflets to the normal atrioventricular junction, and longitudinal plication of the atrialized RV, they provide a very different anatomy and function for the TV. Carpentier mobilized the anterior and inferior TV leaflets, turning them into a mega leaflet, and rotated it partially only to reach the inferior septal region. Therefore, Carpentier's technique ignores the septal leaflet and constructs a bileaflet valve that closes with the ventricular septum[11]. While the cone concept involves the mobilization of all abnormal TV leaflets and the construction of a cone format valve that is attached to the full TV annulus circumference and closes by leaflet-to-leaflet coaptation[16-18]. The magnetic resonance image (MRI) of our first patient, obtained 25 years after the CR, shows the TV cone shape appearance, and its attachment to the normal atrioventricular junction (Figure 2).

Cone Repair After the Starnes Procedure

In 2019, we introduced CR as a novel approach for right ventricular rehabilitation after the Starnes procedure. This was a

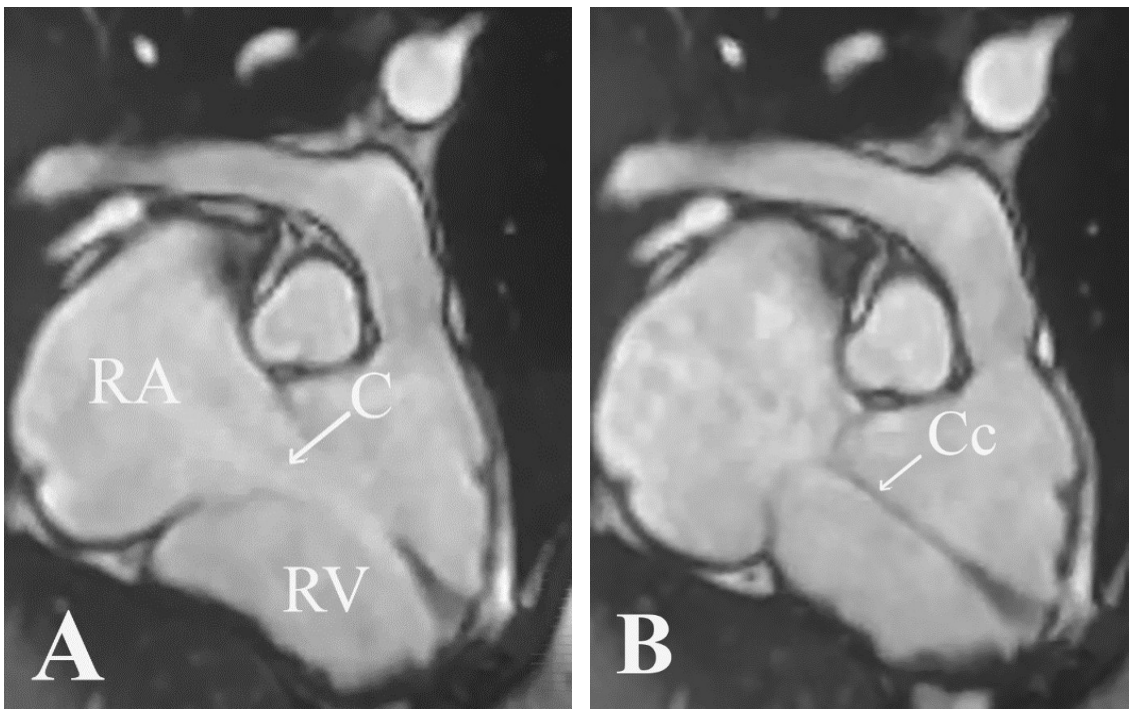

Fig. 2 - *Magnetic resonance imaging on the first patient, 25 years after the Cone repair. (A) Diastolic view of the right ventricle (RV) shows the tricuspid valve cone shape. (B) Systolic view shows a well closed tricuspid valve. C=Cone; Cc=Cone closed; RA=right atrium.*

game-changer in the management of children who received the Starnes procedure as a lifesaving palliation in a critical neonatal condition[24-27]. Before our method, the children with severe EA who underwent the Starnes procedure as neonates used to be committed to the single ventricle pathway, which has a decreased life survival expectancy due to complications related to the Fontan procedure[28,29]. Instead, we pursued the long-term benefits of the two-ventricle circulation, reactivating the RV after the Starnes procedure using the CR technique.

Operative Technique for the Cone Repair

We perform the Cone procedures with bicaval cannulation, moderate hypothermia, and cold blood cardioplegia (usually Del Nido cardioplegic solution). We depicted the CR concepts and the main steps of the cone operation in Figures 3 and 4.

Cone Repair in Ebstein's Anomaly with Complex Anatomy

We can apply the CR to nearly all anatomical variations of EA[16,18,19]. In our experience dealing with over four hundred patients with EA, we encountered only two cases for which the CR could not be applied. One had no TV leaflet at all; the other had a good TV leaflet, but the right ventricular wall had only fat and fibrous tissue, rather than myocardium. We managed the first patient by excluding the dilated RV using the Starnes technique, aiming for a future biventricular repair by implanting a TV prosthesis, while the second patient followed a one-ventricle physiology pathway.
Although the CR concept enabled repair of nearly all anatomical types of EA, some more complex forms require special maneuvers to achieve an efficacious repair. Amongst those are the types C and D on the Carpentier classification. For instance, repairing EA with extreme rotation of the TV into the right ventricular outflow tract is particularly challenging[18]. It requires moving the TV alignment toward the right ventricular apex. In that scenario, we perform the CR by taking down the leaflets as a single piece, retaining only the direct distal linear attachment of the leaflet to the RV. We provide vertical fenestrations at the distal third of this large leaflet. Then, we suture the lateral and medial edges of this leaflet together, creating a cone-like structure. As in all other cases, we close any holes/fenestrations in the proximal two-thirds of the cone's membranous tissues to achieve a similar circumferential depth and to prevent regurgitation leaks. Furthermore, natural, or surgically created fenestrations should be present at the distal one-third of the cone to permit unrestricted blood flow in diastole. Patients with hypoplastic TV leaflets may require leaflet augmentation to achieve an effective repair, *i.e.*, adequate circumference with the cone procedure. The Mayo Clinic group initially reported using either a CorMatrix® membrane or autologous pericardium to enlarge the anterior or septal leaflet. However, they abandoned the use of CorMatrix® due to marked leaflet thickening observed early on in a few patients who required reoperation. At the UPMC Children's Hospital of Pittsburgh, we use fresh or glutaraldehyde-treated autologous pericardium to enlarge the septal leaflet[24,30]. This surgical maneuver appears to help prevent TV stenosis and facilitate valve closure[30]. However, the long-term outcome of the TV leaflet patch augmentation is unknown.

Atrial Septal Defect Treatment

We partially close the persistent foramen ovale (PFO) or atrial septal defect (ASD) in a valved fashion (Figure 1B), allowing blood shunting from right to left in the case of postoperative right ventricular failure[16,18,19]. The opening size of the resulting orifice should be proportional to the degree of right ventricular dysfunction or dilation. We accomplish this with the single-stitch technique for PFO or with a polytetrafluoroethylene (PTFE) patch with an extension flap, which we position in the left atrium to

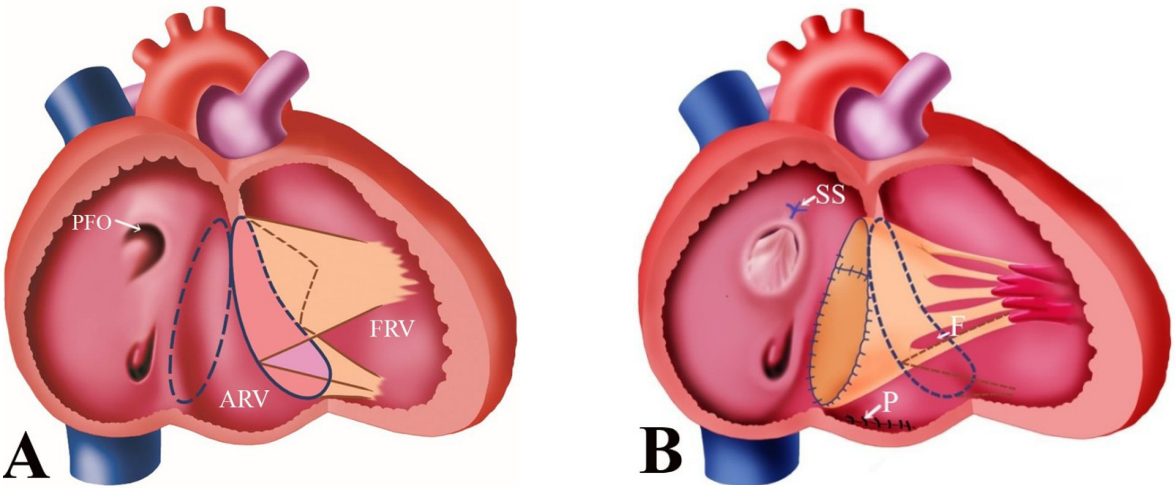

Fig. 3 - *The Cone repair concept. (A) Ebstein's heart with displacement of the TV septal and inferior leaflets, dividing the RV into atrialized and functional chambers. (B) The Cone repair consists of extensive TV leaflet mobilization, keeping only its distal attachments located in a small area near the right ventricular apex. Next, we construct the cone, which is re-attached to the normal atrioventricular junction. Longitudinal plication of the atrialized RV is necessary in most patients. The PFO is closed partially using a single stitch, reestablishing the foramen ovale valve mechanism. ARV=atrialized right ventricle; F=fenestration; FRV=functional right ventricle; P=plication; PFO=persistent foramen ovale; RV=right ventricle; SS=single stitch; TV=tricuspid valve.*

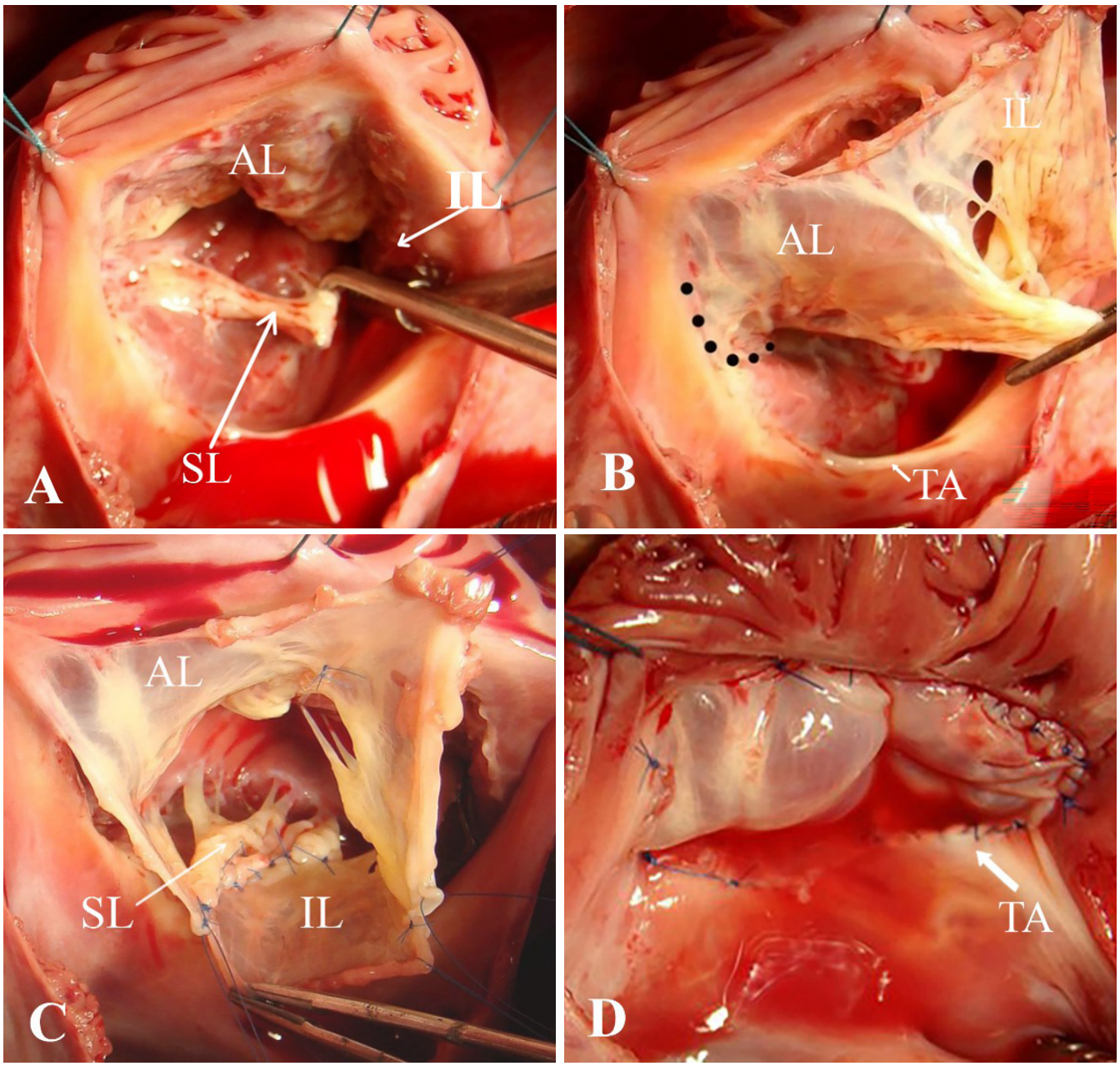

Fig. 4 - *The Da Silva's cone repair main surgical steps. (A) Exposure and assessment of the tricuspid valve by placement of stay sutures just above the true valve annulus at 10, 12, and 3 o'clock positions (10 and 12 go through the pericardium to avoid distortion of the annular plane). (B) Mobilization of the AL connected with the IL by a complete section of abnormal tissues between tricuspid leaflets and ventricular wall, leaving the leaflet attached to the ventricle at its distal margin only (by cords or directly to muscle). Then, we make an anteroseptal incision, at the dotted line, to mobilize the septal leaflet TV. In general, most of the leaflet tissue is detached circumferentially except at 9 to 11 o'clock. This part should be attached to the TA with no tethering to the ventricular wall, allowing free movement. Note that extensive detachment of the leaflet down to its distal point is a critical part of the procedure because it allows to get adequate tissues to construct the cone and gives good mobility to each leaflet. So, the leaflets can move well in systole and close with a good coaptation surface. (C) The cone is constructed by rotating the IL to augment the small septal leaflet. (D) The final result is excellent, no TV regurgitation at the saline injection test. AL=anterior leaflet; IL=inferior leaflet; SL=septal leaflet; TA=true annulus.*

allow unidirectional blood flow toward the left atrium in cases of ASD. In cases of severe right ventricular dysfunction, we place the single stitch near the anterior corner of the PFO, rather than centrally. This will result in a less restrictive PFO and permit greater right-to-left atrial-level shunting. We use the bidirectional Glenn procedure as an adjunct to the repair of Ebstein's malformation in severe dysfunctional right ventricular conditions.

Neonatal Ebstein's Anomaly and the Cone Repair

EA diagnosed during fetal life is associated with high perinatal mortality. A recent multicenter study showed that the risk of fetal demise or neonatal death was approximately 45%[31]. Additionally, multivariable analysis showed that the absence of antegrade pulmonary valve (PV) flow or the presence of pulmonary regurgitation at diagnosis were significant hemodynamic risk factors. Pulmonary regurgitation with a circular shunt was the strongest predictor of perinatal mortality[31]. In a recent Society of Thoracic Surgeons database study by Holst and coauthors examining surgical treatment of neonatal EA, overall mortality was 27.4%, and the mortality related to the primary TV repair was 39.6%[32]. This high mortality in a contemporary era emphasizes the need for continued improvement in this challenging group of patients. Perinatal mortality is due in part to a circular shunt caused by combined pulmonary and tricuspid regurgitation, leading to continuous retrograde ductal flow and intracardiac recirculation, with low tissue perfusion and metabolic acidosis. Therefore, effective treatment of fetuses and neonates with EA with a circular shunt is an urgent task that should start soon after the fetal diagnosis. The high fetal demise rate associated with the circular shunt has encouraged the use of non-steroidal anti-inflammatory drugs given to the mother, which constrict the fetal ductus arteriosus, improving fetal survival[33,34]. A circular shunt in neonates creates hemodynamic instability, with severe hypoxia and low cardiac output syndrome. It requires intubation, paralysis, inotropic support, and usually needs the Starnes procedure[24,34,35]. Newborns with EA requiring prostaglandin or mechanical ventilation, worsening cyanosis or heart failure, and anatomic pulmonary atresia require surgical intervention during the neonatal period[35].

The non-surgical management can be applied to about 30% of neonates with EA. In fact, the initial medical management applies to most neonates presenting in a grave clinical condition in the first week of life. They are immediately intubated, paralyzed, and begin on nitric oxide and prostaglandin E1 to maintain or restore ductal patency, appropriate catecholamine support, aggressive treatment of metabolic acidosis, and other intensive therapy. If the patient's condition does not stabilize, extracorporeal membrane oxygenation (ECMO) should be considered, either before facilitating resuscitation or after emergency surgery[24,35]. Urgent echocardiographic evaluation is indicated to establish the diagnosis and evaluate the right ventricular outflow tract. If antegrade flow through the PV is absent, the pulmonary atresia may be functional (elevated pulmonary vascular resistance coupled with severe tricuspid regurgitation and right ventricular dysfunction) or anatomic[36]. A trial of inhaled nitric oxide is warranted to lower pulmonary vascular resistance and promote antegrade flow through the PV if it is patent[36]. If nitric oxide is helpful in bridging a marginal patient through the neonatal period, the addition of oral sildenafil may be useful. The newborns who receive only medical treatment require medical follow-up and likely surgical intervention in the future.

A patent ductus arteriosus (PDA) stent can be the initial intervention in selected situations when there are inadequate forward pulmonary flow and a competent PV, causing cyanosis but without severe cardiomegaly or left ventricular septal deviation. The PDA stenting procedure can stabilize oxygen saturations, allowing CR later in infancy[35].

The application of CR in neonatal EA should be considered only in highly selected situations, given the procedure's complexity, delicate leaflet tissues, and the associated lung immaturity. When the neonatal CR is considered, it should be applied only to a small, ideal subgroup of older neonates (over two weeks old) who are hemodynamically stable, have favorable TV morphology, have a reasonably sized functional RV with good systolic contractility, and excellent pulmonary artery and valve anatomy. Knott-Craig et al.[37] effectively used a simplified repair in a select group of neonates. Finally, in rare cases, neonatal CR can result in a good outcome and should be managed only by an experienced medical and surgical team. However, most newborns with EA presenting with heart failure should be addressed with the Starnes procedure[38,39]. This operation decompresses the RV, allows more space for the lungs, and is a more predictable and reproducible operation in the hands of most pediatric heart surgeons. This procedure allows decompression of the malformed RV, thereby alleviating ventricular septal impingement on the left ventricle (LV). The Starnes procedure facilitates left ventricular filling, thereby improving the LV's ability to supply the systemic and pulmonary circulations[39]. Any pulmonary regurgitation should be eliminated with the main pulmonary artery ligation, and the coronary sinus must stay on the atrial side of the patch to ensure effective decompression of the RV. Reduction right atrioplasty helps to open space inside the chest for lung expansion/development. The advantages of the Starnes procedure are reflected in improved outcomes. Starnes' group reported survival rates for single ventricle palliation after the Starnes procedure of 87%, 87%, and 81% at one, five, and 10 years, respectively, in 24 patients who underwent the modified Starnes operation with a fenestrated TV patch[29]. This group also highlights the important anatomic changes that occur when the RV is effectively decompressed, such as continuous right ventricular regress in size, and the ventricular septum shifting away from the LV[28].

Currently, children with severe EA who underwent the Starnes procedure as neonates are not committed to the single-ventricle pathway, as we can offer the potential long-term benefits of a two-ventricle circulation by reactivating the RV after the Starnes procedure using the CR technique. Therefore, those very sick EA neonates should undergo a staged form of treatment, which begins with the neonatal Starnes procedure, followed by the Starnes takedown and the CR later[24,27,35].

All EA patients who underwent the Starnes procedure are considered for right ventricular rehabilitation with the cone procedure. After the Starnes procedure, our patients are treated according to the following pathway. Patients with a normal or nearly normal PV undergo a two-ventricle repair. Patients with pulmonary atresia or severe pulmonary stenosis with a small annulus start with the Glenn procedure at age four to six months, and the CR afterward. The recommended age for the subsequent CR after a Starnes-Glenn procedure is 12 to 18 months, to avoid a progressive decrease in right ventricular cavity size[26]. Preoperatively, all patients undergo echocardiography and heart catheterization and must have a cardiac MRI before their Cone procedure. It is also

important to review the initial neonatal echocardiogram to evaluate the untouched TV anatomy and the leaflet tissue availability. The lack of TV leaflet tissue or diffuse right ventricular myocardial fibrosis are contraindications to CR in this patient group. Our experience with the CR after the Starnes is summarized in Table 1. Postoperative TV function in these patients is usually very good, and the need for re-repair is small[25-27]. Of note, the right ventricular volume increases significantly immediately after the CR, and it continues to grow and to improve its function over time[27].

The surgical technique for CR is similar to that for other EA patients, except that right ventricular plication and annuloplasty are unnecessary; a fenestration in the patch is essential when closing the ASD, and right ventricular outflow tract reconstruction is necessary if it is obstructive[24-27]. As the paradigm shifts toward a biventricular future for these patients, it is important to ensure that, at the time of Starnes, the TV and PV tissues are maintained during the initial Starnes procedure. We previously described how we modify elements of the Starnes operation to facilitate this. We prefer PTFE instead of a glutaraldehyde-treated patch because it adheres less to the TV leaflets and can be removed easily without damaging them. We suture the fenestrated PTFE patch in a supravalvular position, suturing it to the Todaro tendon instead of directly to the TV septal annulus to preserve the underlying valve leaflet tissues and reduce the risk of heart block[27,40].

At the time of Starnes, in cases of significant PV insufficiency and circular shunt physiology, we interrupt the pulmonary artery at 3 mm distal to the PV, either by simple ligature or by suturing a PTFE patch 3 mm distal to the PV, as described by Freire and colleagues[40]. This prevents pulmonary artery distortion compared to pulmonary artery division and valve oversewing, facilitating its reconstruction during subsequent two-ventricle repair.

The Cone Repair Results

The CR can be performed with very low hospital mortality. Our first international publication on the CR for EA consisted of 40 patients, having lost one patient, accounting for a hospital mortality rate of 2.5%[16]. We reviewed 208 consecutive non-neonate patients with EA at the Hospital Beneficência Portuguesa in São Paulo, Brazil, from November 1993 to March 2026, and all patients received the CR, except for one adult patient who underwent TV replacement as the initial procedure (0.5%). The hospital mortality rate was 1.9%. Since January 2013, after we modernized our overall care, we have operated on 74 patients without mortality, excluding neonates. The data from our longitudinal study of the first 52 patients showed significant improvement in heart failure functional class (New York Heart Association [NYHA]) after follow-up of 9.6 to 162 months (mean 57.44 ± 45.14 months). The Kaplan-Meier survival curve (Figure 5B), which included hospital mortality, showed a 94.1 ± 3.2% survival at six years of follow-up[19].

At the UPMC Children's Hospital of Pittsburgh, we operated on 183 patients, including neonates, older children, and adults, reoperations, and CR after the Starnes procedure. We had only one hospital death: a patient who underwent a reoperation at 68 years of age, having severe heart failure and significant co-morbidities. Our summarized data and results are shown in Table 1. Other centers of excellence have recently achieved outstanding results by applying the refinements of the cone technique we developed

Table 1. Ebstein's anomaly: age group distribution and clinical outcomes following cone repair at UPMC Children's Hospital of Pittsburgh from March 2016 to April 2026.

Age group	Number (%)	Hospital mortality	Late TV re-repair	Late TVR	Late mortality
Adults	51 (27.9%)	1 (1.96%)	1 (1.96%)	2 (3.9%)	1 (arrhythmia)
(18 – 68 years)					1 (brain tumor)
Children	117 (63.9%)	0	5 (4.27%)	0	1 liver bleeding
(13 months – 18 years)					1 tracheostomy complication
Infants	15 (8.2%)	0	1 (6.67%)	1 (6.7%)	0
(1 – 12 months)					
Total	183	1 (0.54%)	7 (3.28%)	3 (1.6%)	4 (2.10%)
Cone repair after Starnes	24	0	2 (8.33%)		1 (4.17%)
5 – 96 months	(22 included above + 2 operated in Tampa, Florida)				Pre liver transplant, tracheostomy complication

TV=tricuspid valve; TVR=tricuspid valve replacement

This table summarizes the distribution of patients who underwent Cone repair for Ebstein's anomaly at UPMC Children's Hospital of Pittsburgh, categorized by age group (adults, children, and infants). It includes the number and percentage of cases within each age group, as well as data on hospital mortality and changes post-procedure where available. The 22 patients who received the Cone repair after the Starnes procedure at the UPMC Children's Hospital of Pittsburgh are included in the infants and children under 8 years of age groups

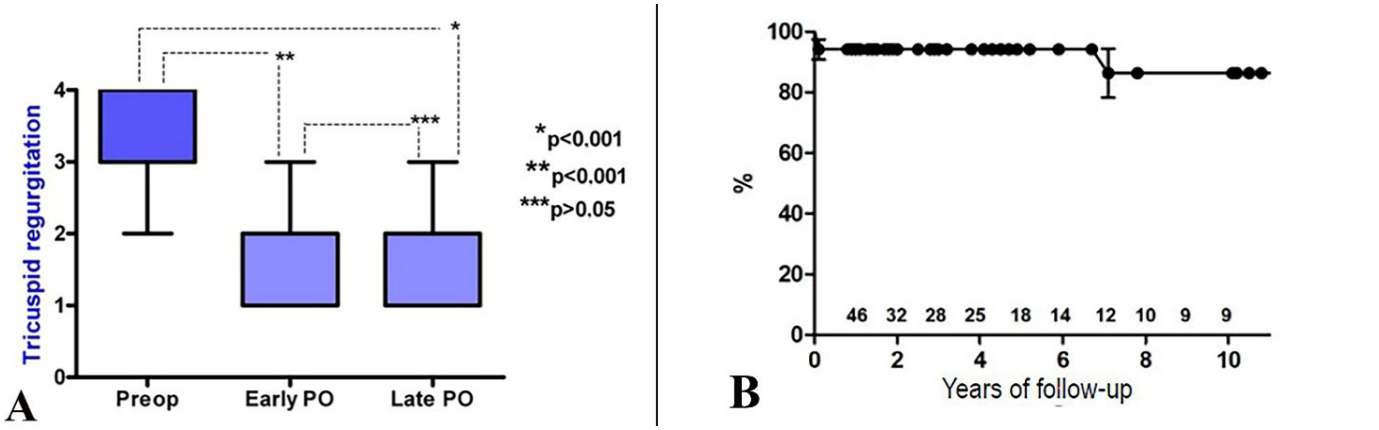

Fig. 5 - *(A) Tricuspid valve regurgitation. Comparison between the preoperative (Preop), early postoperative (PO), and long-term PO periods. Echocardiographic data from the first 52 patients who underwent the Da Silva procedure in Brazil, with a follow-up of 9.6 to 162 months (mean 57.44 months ± 45.14 months), were collected preoperatively, at hospital discharge, and at the last evaluation. Data is presented with mean ± 95% confidence interval. (B) Actuarial survival curve estimated by the Kaplan-Meier method on the same patient series. It shows a survival rate of 94.1 ± 3.2% at a six-year follow-up. Data is presented with standard errors. The number of patients at risk is indicated yearly.*

over the years, updated concepts of perioperative care, and high-tech assist devices[20-22]. The indication for operation has been expanded, using a more rational criterion based on the patient's age and clinical conditions[17,35,41]. This was a consequence of the Da Silva CR cone technique's efficacy and the increased likelihood of repairing rather than replacing the TV.

The Tricuspid Valve Function after the Da Silva Cone Repair

Regarding the TV function after the CR, we have had excellent results, particularly after the surgical refinements achieved over the last 10 years. Tricuspid regurgitation was markedly diminished after repair (Figure 5). TV stenosis was observed in only one patient during long-term follow-up, which was mild on echocardiogram and had no clinical consequences[16,19].

Before CR, recurrent tricuspid regurgitation was considerable. CR was associated with a higher rate of successful repair and a lower incidence of moderate or greater recurrent tricuspid regurgitation at midterm follow-up (Figure 6)[42].

The Right Ventricular Function After the Cone Repair

In our experience, most patients show improvement in right ventricular function postoperatively after an initial decline following the CR. Additionally, there is a tendency towards progressive right ventricular reverse remodeling with a reduction of right ventricular volume[19]. The German Heart Center in Munich reported results from 122 patients operated on from 1976 to 2007, showing that a sustained reduction in tricuspid regurgitation may prompt a progressive decline in right ventricular size and a late improvement in right ventricular function. The MRI studies showed that the mean functional right ventricular end-diastolic volume decreased after surgery (pre 334 [135 – 656] ml; post 175 [115 – 404] ml, $P < 0.001$). The mean right ventricular ejection fraction decreased (pre 47 ± 10%; post 35 ± 13%, $P = 0.001$), and the mean antegrade net stroke volume of the RV increased (pre 65 ± 28 ml; post 75 ± 30 ml, $P = 0.057$). However, even when TV repair is performed early, right ventricular function cannot be restored to a satisfactory level in some cases[21]. Likewise, another study also suggests that the CR technique has a significant impact on right ventricular reverse remodeling and left ventricular work, and sustained benefits in long-term clinical outcomes[43].

The Indications for Da Silva's Cone Repair

Traditionally, surgery for EA was considered for patients with symptoms, declining exercise capacity, NYHA class III or IV heart failure, cyanosis (oxygen saturation ≤ 90%), paradoxical embolism, progressive heart enlargement on chest X-ray (computed tomography ratio 0.6), progressive right ventricular enlargement on echocardiography, or the onset or worsening of atrial or ventricular arrhythmias[16,17]. Usually, asymptomatic patients with near-normal exercise tolerance, no right-to-left shunt, and only mild heart enlargement were just observed. With the advent of Da Silva CR, which offers excellent surgical results, earlier surgery is now often considered, as it carries low risk and closely restores normal anatomy[17]. The recent American Association for Thoracic Surgery (AATS) expert consensus on managing EA, covering the preoperative evaluation, surgical indications, and contraindications in both children and adult patients, is summarized in Table 2[41]. Additionally, the expert consensus made recommendations on the general management strategies, stating that bidirectional cavopulmonary shunt is reasonable when there is severe right ventricular dilation, severe right ventricular systolic dysfunction, right atrial pressure and left atrial pressure ratio > 1.5, or failure to separate from cardiopulmonary bypass following repair. Regarding transcatheter closure of the ASD, they stated that it is not recommended when there is severe tricuspid regurgitation or a severe form of EA.

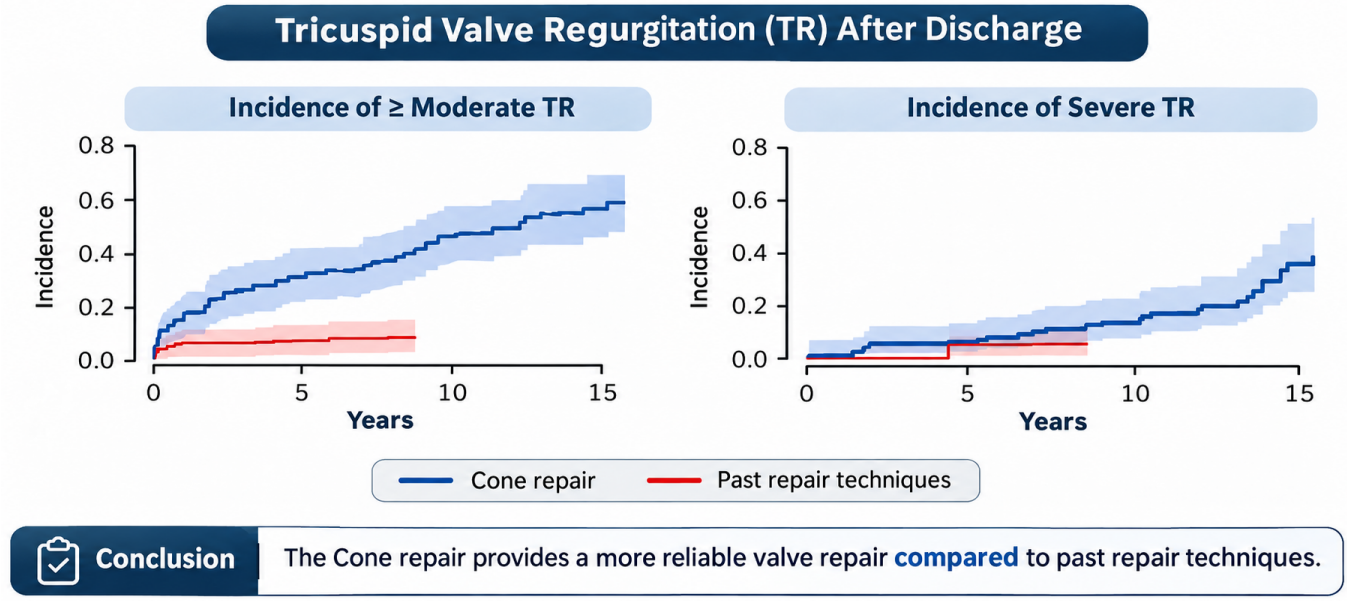

Fig. 6 – *Tricuspid regurgitation after the Cone repair (red) compared to other repair techniques (blue) for Ebstein's anomaly Cumulative incidence of moderate or greater tricuspid regurgitation (TR), severe TR, and reoperation after Cone repair compared with other repair techniques. The 95% confidence intervals are plotted as shades. Study carried out at the Heart Center, Technical University of Munich, Germany. (Modified from Burri M et al. Cone versus conventional repair for Ebstein's anomaly. JTCVS. 2020; 160:1545-1553.)*

COMMENTS

EA presents a wide spectrum of anatomical variations and variable degrees of right ventricular myocardial compromise, making the correction of EA difficult. The repair techniques for EA that resulted in a monocusp valve mechanism had limitations and often required TV replacement[9,10], except for the Carpentier technique, which could be applied to most patients with EA[11,12]. The concerns with the need for TV replacement and its poor results in children resulted in delaying the surgical treatment of EA and allowed the disease to cause progressive right ventricular myocardium damage. However, the Da Silva CR could be applied to nearly all patients with EA, avoiding TV replacement and encouraging early repair[15,16,18,19]. Our initial series in Brazil showed hospital mortality rates of 2.5%, 3.8%, and 1.9% in 40, 52, and 208 patients, respectively[16,19]. Probably, the continuing improvement was related to our expanding experience using the cone concept, but above all to the decreasing mean age of our patients. Of note, we have had no mortality in children (three months to 12 years of age) in our group experience with the CR for EA[19]. Our contemporary results treating EA at UPMC Children's Hospital in Pittsburgh, with very low mortality, also reflect the evolution of patient care technology and the use of ECMO support.

The CR result is better than that of previous repair techniques for EA, with regard to hospital mortality and the need for TV replacement. Considering Danielson's repair, the largest series of EA patients includes 539 patients with 604 operations from 1972 to 2006 at the Mayo Clinic. There, 337 patients (62.5%) underwent TV replacement (89% received bioprosthetic valves and 11% mechanical valves), and 182 patients underwent TV repair. The TV repair was based on a monocusp reconstruction, with surgical technique modifications as required by the EA variant. The 30-day mortality was 5.9% for the entire cohort, but it fell to 2.7% after 2001[9]. After the Mayo Clinic adopted the CR, their first report on 89 patients submitted to the CR showed a hospital mortality rate of 1.1% and TV replacement in six patients (6.7%)[20].

The initial description of Carpentier's technique reported a hospital mortality rate of 14%[11]. In a larger series of 142 EA patients reported by the Carpentier group using the Carpentier technique, the hospital mortality rate was 10%, and only three patients required TV replacement. It is important to note that Carpentier's series consisted mainly of adult patients, with a mean age of 25 +/- 15 years[12]. Quaegebeur et al.[13] performed a slight modification of Carpentier's procedure, omitting the prosthetic ring, and applied the technique in 10 patients. Despite no hospital mortality, they observed a high incidence of moderate and severe degrees of tricuspid regurgitation in the follow-up. In the study by Chen et al.[14] which evaluated 25 patients, 16 echocardiograms were obtained in the mid-term, revealing moderate (18%) and significant (12%) regurgitation, and two patients required valve replacement.

Other centers of excellence have recently achieved outstanding results by using the cone technique with the refinements we developed over the years, applying updated concepts of perioperative care, and employing high-tech assist devices[20,21,30]. As a consequence of the cone technique's efficacy and the increased possibility of repairing rather than replacing the TV, the indication for operation has been expanded, using more rational criteria regarding the patient's age and clinical conditions[17,35,41].

An important accomplishment of the CR is the dependability and the durability of TV function improvements. Our study of the first 52 patients who underwent the CR in Brazil showed a significant early postoperative reduction in the degree of TV regurgitation,

Table 2. The American Association for Thoracic Surgery (AATS) 2025 expert consensus on the management of Ebstein's anomaly in children and adults.

Preoperative assessment	Class of recommendation and level of evidence
In non-neonatal patients with Ebstein's anomaly, the presence of congestive heart failure, cyanosis, significant left ventricular dysfunction (LVEF < 40%), severe cardiomegaly (chest X-ray CTI > 0.65), and persistent arrhythmia increase the risk for morbidity and mortality compared to those without these features.	CoR: I; LoE: B-NR
If feasible, cardiac magnetic resonance imaging is recommended for comprehensive imaging of Ebstein's anomaly for reliable volume assessment of both ventricles and the evaluation of tricuspid regurgitation fraction and right ventricular stroke volume.	CoR: I; LoE: B-NR
Asymptomatic older children and adults with Ebstein's anomaly should undergo exercise stress testing with measurement of oxygen consumption to unmask occult exercise intolerance.	CoR: I; LoE: B-NR
Surgical recommendations and indications for intervention	
Surgery is recommended for symptoms that include fatigue (not attributable to other causes), decreasing objective exercise tolerance (*i.e.*, lower than expected exercise tolerance on exercise testing), decreased arterial oxygen saturation (cyanosis), and exertional dyspnea.	CoR: I; LoE: B-NR
Surgery is recommended when there is severe tricuspid regurgitation and progressive right ventricular dilation or dysfunction on serial echo or MRI.	CoR: I, LoE: B-NR
Surgery can be beneficial in asymptomatic patients when there is severe tricuspid regurgitation, moderate right ventricular enlargement, and valve anatomy favorable for repair.	CoR: IIa; LoE: C-LD
Surgical intervention at 3 - 5 years of age is reasonable when there is severe tricuspid regurgitation, moderate right ventricular enlargement, and a high probability of successful valve repair.	CoR: IIa; LoE: C-LD
Tricuspid valve surgery is not recommended when there is irreversible severe biventricular systolic dysfunction (LVEF < 25%, RVEF < 25%).	CoR: III; LoE: B-NR
Cone repair of the tricuspid valve is beneficial when surgery is indicated.	CoR: I; LoE: B-NR)

CTI=cardiothoracic index; LVEF=left ventricular ejection fraction; MRI=magnetic resonance imaging; RVEF=right ventricular ejection fraction

The AATS expert consensus was developed using the Delphi method, in which an electronic survey is circulated with multiple-choice options based on a Likert scale; each recommendation includes a class of recommendation and a level of evidence. Consensus requires an 80% response rate and at least 75% agreement on class and level

CoR: I = Class of Recommendation I is a strong recommendation; CoR: IIa = Class of Recommendation IIa is a moderate recommendation; CoR: III = Class of Recommendation III means that the procedure is not recommended because the risk is greater than the benefit; LoE: B-NR = Level of Evidence B, non-randomized is moderate-quality evidence from 1 or more well-designed, well-executed nonrandomized studies, observational studies, or registry studies or meta-analyses of such studies; LoE: C-LD = Level of C-LD is based on studies with limitations of design or execution, meta-analysis of such studies, case series, or physiological or mechanistic studies in human subjects

and this result was maintained over the middle-term follow-up, indicating that TV repair using the cone technique is effective and durable[19].

Regarding the right ventricular function in EA, it is known that right ventricular abnormality is part of the disease[44]. Pathological right ventricular changes can originate during embryological development in severe EA or be acquired or aggravated in mild or moderate EA because of long-standing TV regurgitation. Structural right ventricular myocardial changes have been described in EA, which may be accountable for reduced right ventricular performance. In this context, we partially close the foramen oval or ostium secundum ASDs in a valved fashion to allow for a reduced degree of right-to-left shunting[16,18,19]. This may cause some degree of oxygen desaturation, but can help increase cardiac output in the set-

ting of early right ventricular dysfunction often observed after the CR. Once the right ventricular function improves, the right-to-left shunting at the atrial septum disappears, and oxygen saturation normalizes. This strategy of right ventricular decompression made the cavopulmonary shunt procedure, or Glenn procedure, less necessary in our patients. However, we recommend the adjunctive Glenn procedure in patients with severe preoperative right ventricular dysfunction or in those who present postoperatively with dysfunction causing significant oxygen desaturation (≤ 85%) due to large right-to-left shunting through the atrial septal communication. This follows the concept introduced by Chauvaud et al.[45], who reported better results with bidirectional cavopulmonary anastomosis, together with Carpentier's operation, in patients with severe right ventricular dysfunction. These authors used this technique in 36% of patients to decrease the right ventricular preload in cases of severe right ventricular dysfunction, thereby achieving a significant reduction in mortality from right ventricular failure. Some surgeons also use the Glenn procedure in children with TV repair resulting in significant regurgitation. We agree that the Glenn procedure can mitigate the effects of significant TV regurgitation after repair in children, avoiding TV replacement in this group of patients. However, we haven't used this procedure for that reason yet.

Further research is needed to clarify the postoperative right ventricular remodeling in different ages and anatomical subsets of EA. Longitudinal studies using serial MRI techniques are of paramount importance for elucidating questions about right ventricular dysfunction and may guide tailored treatment to the patient's individual needs.

Regarding the application of the CR in special situations, it has been substantially expanded in recent years. Currently, the operation can be performed in complex anatomical subsets of the malformation, even in cases of extreme rotation of the TV into the right ventricular outflow tract[19]. In the past, this anatomical type of EA was considered irreparable with the monocusp repair procedure developed by Danielson and colleagues, and this became an echocardiographic criterion for TV replacement[9].

The CR can also be performed in patients with previous valve surgery if the subvalvar apparatus has been preserved, as previous repair operations focused on annular maneuvers, and even in TV replacement that has conserved enough valve tissue to construct a cone structure[46].

Our innovative approach to rehabilitating the RV that had been excluded in the lifesaving Starnes procedure in the neonatal period demonstrated the feasibility of an eventual two-ventricle physiology, setting the way for a staged treatment of neonates with severe forms of EA[24-27]. Actually, the cone procedure can be used for right ventricular rehabilitation even in selected symptomatic patients who underwent the Fontan procedure following the Glenn and the Starnes procedures[47]. The possibility of biventricular repair, which offers a better prognosis than the single-ventricle pathway, encourages more Starnes procedures for critical neonatal EA, resulting in decreased perinatal mortality and, consequently, improved long-term outcomes.

Although long-term follow-up data on the Da Silva CR are limited, the AATS, 2025 expert consensus on the management of EA in children and adults concluded that the introduction of the cone procedure has revolutionized its surgical management, providing excellent outcomes and durability across a wide range of anatomical variations[41]. Currently, we are conducting a longitudinal study of 230 EA patients who underwent CR from 1993 to 2016. This study is likely to provide more definitive information on the CR's impact on EA treatment.

CONCLUSION

The CR can be performed in nearly all anatomical variations of EA with low mortality and morbidity. The repair is effective and durable, with rare need for TV replacement. Neonates with critical EA may benefit from a staged approach, performing the Starnes procedure in the neonatal period and CR later. CR after TV prosthesis implantation may be viable, encouraging preservation of most leaflet tissue during TV replacement in EA.

Data Availability

The authors declare that the data supporting the findings of this study are available within the article.

Artificial Intelligence Usage

The authors declare that no artificial intelligence tool was used in the preparation of this article.

Sources of Funding

The authors declare no external funding to this study.

Potential Conflict of Interest

The authors declare that there is no conflict of interest in this study.

Authors' Roles & Responsibilities

JPS	Substantial contributions to the conception or design of the work; or the acquisition, analysis, or interpretation of data for the work; drafting the work or revising it critically for important intellectual content; agreement to be accountable for all aspects of the work in ensuring that questions related to the accuracy or integrity of any part of the work are appropriately investigated and resolved; final approval of the version to be published
VM	Substantial contributions to the conception or design of the work; or the acquisition, analysis, or interpretation of data for the work; drafting the work or revising it critically for important intellectual content; agreement to be accountable for all aspects of the work in ensuring that questions related to the accuracy or integrity of any part of the work are appropriately investigated and resolved; final approval of the version to be published
MMC	Substantial contributions to the conception or design of the work; or the acquisition, analysis, or interpretation of data for the work; drafting the work or revising it critically for important intellectual content; agreement to be accountable for all aspects of the work in ensuring that questions related to the accuracy or integrity of any part of the work are appropriately investigated and resolved; final approval of the version to be published
MCM	Substantial contributions to the conception or design of the work; or the acquisition, analysis, or interpretation of data for the work; drafting the work or revising it critically for important intellectual content; agreement to be accountable for all aspects of the work in ensuring that questions related to the accuracy or integrity of any part of the work are appropriately investigated and resolved; final approval of the version to be published

RFB Substantial contributions to the conception or design of the work; or the acquisition, analysis, or interpretation of data for the work; drafting the work or revising it critically for important intellectual content; agreement to be accountable for all aspects of the work in ensuring that questions related to the accuracy or integrity of any part of the work are appropriately investigated and resolved; final approval of the version to be published

RMC Substantial contributions to the conception or design of the work; or the acquisition, analysis, or interpretation of data for the work; drafting the work or revising it critically for important intellectual content; agreement to be accountable for all aspects of the work in ensuring that questions related to the accuracy or integrity of any part of the work are appropriately investigated and resolved; final approval of the version to be published

JCG Substantial contributions to the conception or design of the work; or the acquisition, analysis, or interpretation of data for the work; drafting the work or revising it critically for important intellectual content; agreement to be accountable for all aspects of the work in ensuring that questions related to the accuracy or integrity of any part of the work are appropriately investigated and resolved; final approval of the version to be published

LFS Substantial contributions to the conception or design of the work; or the acquisition, analysis, or interpretation of data for the work; drafting the work or revising it critically for important intellectual content; agreement to be accountable for all aspects of the work in ensuring that questions related to the accuracy or integrity of any part of the work are appropriately investigated and resolved; final approval of the version to be published

REFERENCES

1. Ebstein W. Ueber einen sehr seltenen Fall von Insufficient der valvula tricuspidalis, bedingt durch eine angedorene hochgradige missbildung derselben. Arch Anat Physiol. 1866:238-254. Available from: https://www.biodiversitylibrary.org/page/35345710.
2. Schreiber C, Cook A, Ho SY, Augustin N, Anderson RH. Morphologic spectrum of Ebstein's malformation: revisitation relative to surgical repair. J Thorac Cardiovasc Surg. 1999;117(1):148-55. doi:10.1016/S0022-5223(99)70480-0.
3. Hunter SW, Lillehei CW. Ebstein's malformation of the tricuspid valve; study of a case together with suggestion of a new form of surgical therapy. Dis Chest. 1958;33(3):297-304. doi:10.1378/chest.33.3.297.
4. Hardy KL, May IA, Webster CA, Kimball KG. Ebstein's anomaly: a functional concept and successful definitive repair. J Thorac Cardiovasc Surg. 1964;48:927-40. PMID:14239982..
5. Hardy KL, Roe BB. Ebstein's anomaly: further experience with definitive repair. 1969;58(4):553-61. PMID:5344191.
6. Bahnson HT, Bauersfeld SR, Smith JR. Pathological anatomy and surgical correction of Ebstein's anomaly. Circulation. 1965;31(Suppl 1):I-3-I-8. doi:10.1161/01.cir.31.4s1.i-3.
7. McFaul RC, Davis Z, Giuliani ER, Ritter DG, Danielson GK. Ebstein's malformation. Surgical experience at the Mayo Clinic. J Thorac Cardiovasc Surg. 1976;72:910. PMID:994541.
8. Danielson GK, Driscoll DJ, Mair DD, et al. Operative treatment of Ebstein malformation. Danielson GK, Driscoll DJ, Mair DD, et al. Operative treatment of Ebstein malformation. J Thorac Cardiovasc Surg. 1992;104:1195-202. doi:10.1016/S0022-5223(19)34605-7.
9. Brown ML, Dearani JA, Danielson GK, Cetta F, Connolly HM, Warnes CA, Li Z, Hodge DO, Driscoll DJ; Mayo Clinic Congenital Heart Center. The outcomes of operations for 539 patients with Ebstein anomaly. J Thorac Cardiovasc Surg. 2008;135(5):1120-36. doi:10.1016/j.jtcvs.2008.02.034.
10. Boston US, Dearani JA, O'Leary PW, Driscoll DJ, Danielson GK. Tricuspid valve repair for Ebstein's anomaly in young children: a 30-year experience. Ann Thorac Surg. 2006;81(2):690-6. doi:10.1016/j.athoracsur.2005.08.011.
11. Carpentier A, Chauvaud S, Macé L, Relland J, Mihaileanu S, Marino JP, Abry B, Guibourt P. A new reconstructive operation for Ebstein's anomaly of the tricuspid valve. J Thorac Cardiovasc Surg. 1988;96(1):92-101. PMID:3386297
12. Chauvaud S. Ebstein's malformation. Surgical treatment and results. Thorac Cardiovasc Surg. 2000;48(4):220-3. doi:10.1055/s-2000-6892.
13. Quaegebeur JM, Sreenam N, Fraser AG, Bogers AJ, Stumper OF, Hess J, et al. Surgery for Ebstein's anomaly: the clinical and echocardiographic evaluation of a new technique. J Am Coll Cardiol. 1991;17(3):722-8. doi:10.1016/S0735-1097(10)80190-1.
14. Chen JM, Mosca RS, Altman K, Printz BF, Targoff K, Mazzeo PA, et al. Early and medium-term results for repair of Ebstein anomaly. Early and medium-term results for repair of Ebstein anomaly. J Thorac Cardiovasc Surg. 2004;127(4):990-8; discussion 998-9. doi:10.1016/j.jtcvs.2003.11.037.. 2004;127(4):990-9.
15. Silva JP, Baumgratz JF, Fonseca Ld, Afiune JY, Franchi SM, Lopes LM, Magalhães DM, Vila JH. Anomalia de Ebstein: resultados com a reconstrução cônica da valva tricúspide [Ebstein's anomaly: results of the conic reconstruction of the tricuspid valve]. Arq Bras Cardiol. 2004;82(3):212-6. Portuguese. doi:10.1590/S0066-782X2004000300002.
16. Da Silva JP, Baumgratz JF, da Fonseca L, Franchi SM, Lopes LM, Tavares GM, et al. The cone reconstruction of the tricuspid valve in Ebstein's anomaly: the operation: early and midterm results. J Thorac Cardiovasc Surg. 2007;133(1):215-23. doi:10.1016/j.jtcvs.2006.09.018.
17. Dearani JA, Bacha EA, da Silva JP. Cone reconstruction of the tricuspid valve for Ebstein's anomaly: anatomic repair. Oper Tech Thorac Cardiovasc Surg. 2008;13(2):109-25. doi:10.1053/j.optechstcvs.2008.03.003.
18. Da Silva JP, da Silva LF. Ebstein's anomaly of the tricuspid valve: the cone repair. Semin Thorac Cardiovasc Surg Pediatr Card Surg Annu. 2012;15(1):38-45. doi:10.1053/j.pcsu.2012.01.008.
19. Silva JP, Silva LF, Moreira LF, Lopez LM, Franchi SM, Lianza AC, et al. Cone reconstruction in Ebstein's anomaly repair: early and long-term results. Arq Bras Cardiol. 2011;97(3):199-208. doi:10.1590/S0066-782X2011005000084.
20. Dearani JA, Said SM, O'Leary PW, Burkhart HM, Barnes RD, Cetta F. Anatomic repair of Ebstein's malformation: lessons learned with cone reconstruction. Ann Thorac Surg. 2013;95(1):220-6; discussion 226-8. doi:10.1016/j.athoracsur.2012.04.146.
21. Lange R, Burri M, Eschenbach LK, Badiu CC, da Silva JP, Nagdyman N, et al. Da Silva's cone repair for Ebstein's anomaly: effect on right ventricular size and function. Eur J Cardiothorac Surg. 2015;48(2):316-20; discussion 320-1. doi:10.1093/ejcts/ezu472.
22. Li X, Wang SM, Schreiber C, Cheng W, Lin K, Sun JY, et al. More than valve repair: effect of cone reconstruction on right ventricular geometry and function in patients with Ebstein malformation. Int J Cardiol. 2016;206:131-7. doi:10.1016/j.ijcard.2016.01.032.
23. Silva GVRD, Miana LA, Caneo LF, Turquetto ALR, Tanamati C, Penha JG, et al. Early and long-term outcomes of surgical treatment of Ebstein's anomaly. Braz J Cardiovasc Surg. 2019;34(5):511-6. doi:10.21470/1678-9741-2018-0333.
24. Da Silva JP, Viegas M, Castro-Medina M, da Silva LDF. The Da Silva cone operation after the Starnes procedure for Ebstein's anomaly: new surgical strategy and initial results. JTCVS Tech. 2020;3:281-3. doi:10.1016/j.xjtc.2020.05.011.
25. Dobson CP, Christopher AB, Castro-Medina M, Viegas ML, Da Silva JP, Da Silva LDF. Using DaSilva cone operation to establish 1.5 or 2 ventricle circulation after initial single ventricle palliation with Starnes procedure. Pediatr Cardiol. 2025;46(1):107-15. doi:10.1007/s00246-023-03336-1.
26. Ashraf SF, Da Silva JP, Castro-Medina M, Viegas M, Alsaied T, Seese L, et al. The cone repair allows right ventricle rehabilitation with excellent tricuspid valve function following the Starnes procedure. J Thorac Cardiovasc Surg. 2025;169(2):354-61.e3. doi:10.1016/j.jtcvs.2024.08.024.

27. Da Silva LDF, Morell V, Medina MC, Da Silva JP. Staged treatment for critically ill neonates with Ebstein anomaly: cone repair after Starnes procedure. Semin Thorac Cardiovasc Surg Pediatr Card Surg Annu. 2025;28:38-45. doi:10.1053/j.pcsu.2025.02.007.
28. Reemtsen BL, Polimenakos AC, Fagan BT, Wells WJ, Starnes VA. Fate of the right ventricle after fenestrated right ventricular exclusion for severe neonatal Ebstein anomaly. J Thorac Cardiovasc Surg. 2007;134:1406-12. doi:10.1016/j.jtcvs.2007.07.047.
29. Kumar SR, Kung G, Noh N, Castillo N, Fagan B, Wells WJ, et al. Single-ventricle outcomes after neonatal palliation of severe Ebstein anomaly with modified Starnes procedure. Circulation. 2016;134(17):1257-64. doi:10.1161/CIRCULATIONAHA.115.021241.
30. Stoll VK, Da Silva JP, Sundaram K, Diaz-Castrillon CE, Schiff M, Thoma F, et al. Septal leaflet augmentation during Da Silva cone repair: valvar function and anatomic features compared to nonpatch repair. J Thorac Cardiovasc Surg. 2026;172(2):247-56.e2. doi:10.1016/j.jtcvs.2026.02.035.
31. Freud LR, Escobar-Diaz MC, Kalish BT, Komarlu R, Puchalski MD, Jaeggi ET, et al. Outcomes and predictors of perinatal mortality in fetuses with Ebstein anomaly or tricuspid valve dysplasia in the current era: a multicenter study. Circulation. 2015;132(6):481-9. doi:10.1161/CIRCULATIONAHA.115.015839.
32. Holst KA, Dearani JA, Said SM, et al. Surgical management and outcomes of Ebstein malformation in neonates and infants: a Society of Thoracic Surgeons Congenital Heart Surgery Database analysis. Ann Thorac Surg. 2018;106(3):785-91. doi:10.1016/j.athoracsur.2018.04.049.
33. Torigoe T, Mawad W, Seed M, Ryan G, Marini D, Golding F, et al. Treatment of fetal circular shunt with non-steroidal anti-inflammatory drugs. Ultrasound Obstet Gynecol. 2019;53(6):841-6. doi:10.1002/uog.20169.
34. Lopes LM, Bezerra RF, da Silva JP, da Fonseca da Silva L. Critical Ebstein's anomaly with circular shunt: from successful fetal therapy with non-steroidal anti-inflammatory drugs to biventricular repair using Da Silva cone technique. Cardiol Young. 2021;31(6):1039-42. doi:10.1017/S1047951121000081
35. Konstantinov IE, Chai P, Bacha E, Caldarone CA, Da Silva JP, Da Fonseca Da Silva L, et al. The American Association for Thoracic Surgery (AATS) 2024 expert consensus document: management of neonates and infants with Ebstein anomaly. J Thorac Cardiovasc Surg. 2024;168(2):311-24. doi:10.1016/j.jtcvs.2024.04.018.
36. Jaquiss RDB, Imamura M. Management of Ebstein's anomaly and pure tricuspid insufficiency in the neonate. Semin Thorac Cardiovasc Surg. 2007;19(3):258-63. doi:10.1053/j.semtcvs.2007.07.004.
37. Knott-Craig CJ, Goldberg SP. Management of neonatal Ebstein's anomaly. Semin Thorac Cardiovasc Surg Pediatr Card Surg Annu. 2007:112-6. doi:10.1053/j.pcsu.2007.01.008.
38. Starnes VA, Pitlick PT, Bernstein D, Griffin ML, Choy M, Shumway NE. Ebstein's anomaly appearing in the neonate: a new surgical approach. J Thorac Cardiovasc Surg. 1991;101:1082-7.
39. Reemtsen BL, Fagan BT, Wells WJ, Starnes VA. Current surgical therapy for Ebstein anomaly in neonates. J Thorac Cardiovasc Surg. 2006;132(6):1285-90. doi:10.1016/j.jtcvs.2006.08.044.
40. Bezerra RF, da Silva JP, da Silva LF. Modified Starnes procedure with patch occlusion of the main pulmonary artery and other technical modifications to facilitate subsequent biventricular repair of Ebstein anomaly. Oper Tech Thorac Cardiovasc Surg. 2024;29(3):249-58. doi:10.1053/j.optechstcvs.2023.12.005.
41. Chai P, Konstantinov IE, da Fonseca da Silva L, Qureshi M, Wackel P, Knott-Craig C, et al. The American Association for Thoracic Surgery (AATS) 2025 expert consensus document: management of Ebstein anomaly in children and adults. J Thorac Cardiovasc Surg. 2025;170(1):1-16. doi:10.1016/j.jtcvs.2025.03.014.
42. Burri M, Mrad Agua K, Cleuziou J, Beran E, Nagdyman N, Kühn A, et al. Cone versus conventional repair for Ebstein's anomaly. J Thorac Cardiovasc Surg. 2020;160(6):1545-53. doi:10.1016/j.jtcvs.2020.05.032.
43. Neijenhuis RML, Tsang VT, Marek J, Issitt R, Bonello B, Von Klemperer K, et al. Cone reconstruction for Ebstein anomaly: late biventricular function and possible remodeling. J Thorac Cardiovasc Surg. 2021;161(3):1097-108. doi:10.1016/j.jtcvs.2020.10.124.
44. Anderson KR, Lie JT. The right ventricular myocardium in Ebstein's anomaly: a morphometric histopathologic study. Mayo Clin Proc. 1979;54:181.
45. Chauvaud S, Fuzellier JF, Berrebi A, et al. Bi-directional cavopulmonary shunt associated with ventriculo and valvuloplasty in Ebstein's malformation: benefits in high risk patients. Eur J Cardiothorac Surg. 1998;13:514-9. doi: 10.1016/s1010-7940(98)00057-8.
46. Da Fonseca Da Silva L, Da Silva JP, Seese L, Guerrero Becerra AF, Castro-Medina M, Viegas M, et al. Cone repair after tricuspid valve replacement in Ebstein anomaly. JTCVS Tech. 2023;20:150-2. doi:10.1016/j.xjtc.2023.04.010.
47. Da Silva JP, Seese L, Olivieri L, Al-Sayed T, Kreutzer J, Castro Medina M, et al. The cone repair after Fontan procedure: conversion from completed single-ventricle pathway after the Starnes procedure to biventricular physiology. JTCVS Tech. 2025;33:195-8. doi:10.1016/j.xjtc.2025.05.030.

This is an open-access article distributed under the terms of the Creative Commons Attribution License.